

CONSENSUS DOCUMENT

EHRA/HRS Expert Consensus on Catheter Ablation of Ventricular Arrhythmias

Developed in a partnership with the European Heart Rhythm Association (EHRA), a Registered Branch of the European Society of Cardiology (ESC), and the Heart Rhythm Society (HRS); in collaboration with the American College of Cardiology (ACC) and the American Heart Association (AHA)

Etienne M. Aliot, MD, FESC, FHRS,¹ William G. Stevenson, MD, FHRS,² Jesus Ma Almendral-Garrote, MD, PhD,³ Frank Bogun, MD,⁴ C. Hugh Calkins, MD, FHRS,⁵ Etienne Delacretaz, MD, FESC,⁶ Paolo Della Bella, MD, PhD, FESC,⁷ Gerhard Hindricks, MD, PhD,⁸ Pierre Jaïs, MD, PhD,⁹ Mark E. Josephson, MD,¹⁰ Josef Kautzner, MD, PhD,¹¹ G. Neal Kay, MD,¹² Karl-Heinz Kuck, MD, PhD, FESC, FHRS,¹³ Bruce B. Lerman, MD, FHRS,¹⁴ Francis Marchlinski, MD, FHRS,¹⁵ Vivek Reddy, MD,¹⁶ Martin-Jan Schalij, MD, PhD,¹⁷ Richard Schilling, MD,¹⁸ Kyoko Soejima, MD,¹⁹ and David Wilber, MD²⁰

¹CHU de Nancy, Hôpital de Brabois, Vandoeuvre-les-Nancy, France; ²Brigham and Women's Hospital, Boston, MA, USA; ³Hospital General Gregorio Marañon, Madrid, Spain; ⁴University of Michigan Health System, Ann Arbor, MI, USA; ⁵Johns Hopkins Hospital, Baltimore, MD, USA; ⁶University Hospital, Bern, Switzerland; ⁷Università degli Studi, Centro Cardiologico F. Monzino, Milan, Italy; ⁸University of Leipzig, Heartcenter, Leipzig, Germany; ⁹Hôpital du Haut Leveque, Bordeaux, France; ¹⁰Beth Israel Deaconess Medical Center, Boston, MA, USA; ¹¹Institute For Clinical And Experimental Medicine (Ikem), Prague, Czech Republic; ¹²University of Alabama, Birmingham, AL, USA; ¹³Asklepios Hospital St Georg, Hamburg, Germany; ¹⁴Cornell University Medical Center, New York, NY, USA; ¹⁵University of Pennsylvania, Philadelphia, PA, USA; ¹⁶University of Miami, Miami, FL, USA; ¹⁷Leiden University Medical Center, Leiden, The Netherlands; ¹⁸Barts and the London NHS Trust, UK; ¹⁹University of Miami, Miami, FL, USA; and ²⁰Loyola University Medical Center, Maywood, IL, USA

Preamble

The purpose of this Consensus Statement is to provide a state-of-the-art review of the field of catheter ablation of ventricular tachycardia (VT), and to report the findings of a Task Force, convened by the European Heart Rhythm Association (EHRA) and the Heart Rhythm Society (HRS) that was charged with defining the indications, techniques, and outcomes of this procedure. This statement summarizes the opinion of the Task Force members based on their own experience in treating patients, as well as a review of the literature. It is directed to all healthcare professionals who treat patients who are considered for catheter ablation of VT. This statement is not intended to recommend or promote catheter ablation of VT. Rather, the ultimate judgment regarding care of a particular patient must be made by the healthcare provider and the patient with consideration of the individual patient characteristics that impact on risks and benefits of the therapy. In writing a 'consensus' docu-

ment, it is recognized that consensus does not mean that there was complete agreement among all Task Force members. We identified those aspects of VT ablation for which a true 'consensus' could be identified. Surveys of the entire Task Force were used to identify these areas of consensus. For the purposes of this Consensus Document, we defined a consensus as 70% or greater agreement by the members of this task force. One objective of this document is to improve patient care by summarizing the foundation of knowledge for those involved with catheter ablation of VT. All members of the Task Force, as well as peer reviewers of the document, were asked to provide disclosure statements of all relationships that might be perceived as real or potential conflicts of interest. Disclosures for the members of the task force are given in the Appendix section.

TABLE OF CONTENTS

I. INTRODUCTION	887
II. VENTRICULAR TACHYCARDIA: DEFINITIONS, MECHANISMS, AND RATIONALE FOR ABLATION.....	887

Endorsed by the Heart Rhythm Society, the European Heart Rhythm Association, a registered branch of the European Society of Cardiology, the American Heart Association and the American College of Cardiology.

III. INDICATIONS FOR CATHETER ABLATION OF VENTRICULAR TACHYCARDIA.....	891
IV. TECHNICAL ASPECTS.....	891
V. VENTRICULAR TACHYCARDIA IN STRUCTURAL HEART DISEASE.....	899
VI. ABLATION OUTCOMES AND CONSIDERATIONS IN SPECIFIC DISEASES.....	908
VII. IDIOPATHIC VENTRICULAR TACHYCARDIAS.....	913
VIII. TRAINING AND INSTITUTIONAL REQUIREMENTS AND COMPETENCIES.....	916
IX. CLINICAL TRIAL CONSIDERATIONS.....	918
X. CONCLUSIONS.....	921
APPENDIX.....	922
REFERENCES.....	923
FIGURES.....	889, 890, 900, 906, 909
TABLES.....	888, 891, 920

I. Introduction

Catheter ablation is now an important option to control recurrent ventricular tachycardias (VTs). The field has evolved rapidly and is a work in progress. Ablation is often a sole therapy of VT in patients without structural heart disease and is commonly combined with an implantable cardioverter-defibrillator (ICD) and/or antiarrhythmic therapy for scar-related VTs associated with structural heart disease. As the field progresses, it is important that the medical profession play a significant role in critically evaluating therapies as they are introduced and evolve. Rigorous and expert analysis of the available data documenting indications, techniques, benefits and risks, and outcomes can produce helpful guidance to improve the effectiveness of care, optimize patient outcomes, and identify areas for improvement and future research.

II. Ventricular tachycardia: definitions, mechanisms, and rationale for ablation

Definitions

Many terms have entered clinical usage to describe observations during mapping and ablation of VT. There has been substantial variation in the use of some terms by different investigators. The committee felt that these terms should be standardized to facilitate better understanding of methods, endpoints, and outcomes across centres (Table 1 and Figure 1).¹⁻⁴

Mechanisms and basis for catheter ablation of ventricular tachycardia

Monomorphic VT can occur in individuals with or without structural heart disease. The underlying heart disease and clinical characteristics of the VT often suggest a potential mechanism and origin. Ventricular tachycardias that are due to automaticity are expected to have a focal origin, making them susceptible to ablation with discrete radiofrequency (RF) lesions.⁵⁻¹² Triggered activity or automaticity are likely causes of focal origin VTs, although small reentry circuits can often not be excluded. Idiopathic outflow tract

(OT)-VTs have a focal origin. Relatively large reentry circuits are common in VT associated with ventricular scar, such as prior infarction, but VT may appear focal if the reentry circuit is small, or due to a focal endocardial breakthrough from an epicardial reentry circuit. Automaticity can occur in some patients with ventricular scars.

Triggered activity and automaticity

Triggered activity arises from oscillations in membrane potential during (early afterdepolarizations) or following (delayed afterdepolarizations) an action potential. Experimental evidence implicates early afterdepolarizations in the initiation of polymorphic tachycardias in the long QT syndromes.¹³ However, the mechanism of the premature ventricular beats targeted for ablation in these syndromes is unknown.¹⁴

Delayed afterdepolarizations can be caused by intracellular calcium overload which activates the $\text{Na}^+/\text{Ca}^{2+}$ exchanger resulting in the transient inward current I_{ti} .¹⁻⁴ Factors that increase intracellular calcium include increases in heart rate, β -adrenergic stimulation, and digitalis. β -Adrenergic effects are mediated through a cAMP-induced increase in intracellular calcium and are antagonized by adenosine, which effects a decrease in cAMP. Termination of idiopathic right ventricular outflow tract (RVOT) tachycardias by an intravenous bolus of adenosine or infusion of calcium channel blockers, or by vagotonic manoeuvres is consistent with triggered activity as the likely mechanism for some of these tachycardias.³ These tachycardias can be difficult to induce at electrophysiology (EP) testing; rapid burst pacing and/or isoproterenol infusion is often required. Aminophylline, calcium infusion, and atropine may also be useful.¹⁵

Less commonly, focal VT may be due to automaticity that is provoked by adrenergic stimulation that is not triggered.^{1,15} This type of VT may become incessant under stress or during isoproterenol administration, but cannot be initiated or terminated by programmed electrical stimulation; it can sometimes be suppressed by calcium channel blockers or β -blockers. In contrast to its effects on triggered RVOT tachycardia, adenosine transiently suppresses the arrhythmia but does not *terminate* it.^{1,15} Automaticity from damaged Purkinje fibres has been suggested as a mechanism for some catecholamine-sensitive, focal origin VTs.^{16,17} Whether these VTs are due to abnormal automaticity, originating from partially depolarized myocytes, as has been shown for VTs during the early phase of myocardial infarction (MI), is not clear.

Although automaticity is often associated as a mechanism of VT in the absence of overt structural heart disease, disease processes that diminish cell-to-cell coupling are likely to facilitate automaticity.^{18,19} Automatic VTs can occur in structural heart disease,¹⁷ and automatic premature beats may initiate reentrant VTs.

Scar-related reentry

The majority of sustained monomorphic VTs (SMVTs) in patients with structural heart disease are due to reentry

Table 1 Definitions**Clinical characteristics**

Clinical ventricular tachycardia (VT): VT that has occurred spontaneously based on analysis of 12-lead ECG QRS morphology and rate. There are many potential problems and assumptions with this designation as it is applied to inducible VT in the electrophysiology laboratory (see Endpoints for ablation section).

Haemodynamically unstable VT causes haemodynamic compromise requiring prompt termination.

Idiopathic VT is a term that has been used to indicate VT that is known to occur in the absence of clinically apparent structural heart disease.

Idioventricular rhythm is three or more consecutive beats at a rate of <100/min that originate from the ventricles independent of atrial or AV nodal conduction.

Incessant VT is continuous sustained VT that recurs promptly despite repeated intervention for termination over several hours.

Non-clinical VT is a term that has been used to indicate a VT induced by programmed ventricular stimulation that has not been documented previously. This term is problematic because some VTs that have not been previously observed will occur spontaneously.²⁶² It is recommended that this term can be avoided. Induced VTs with a QRS morphology that has not been previously observed should be referred to as 'undocumented VT morphology'.

Non-sustained VT terminates spontaneously within 30 s.

Presumptive clinical VT is similar to a spontaneous VT based on rate and ECG or electrogram data available from ICD interrogation, but without the 12-lead ECG documentation of either the induced or spontaneous VT.

Repetitive monomorphic VT: continuously repeating episodes of self-terminating non-sustained VT.^{378,462}

Sustained VT: continuous VT for ≥ 30 s or that requires an intervention for termination (such as cardioversion).

Ventricular tachycardia: a tachycardia (rate >100/min) with three or more consecutive beats that originates from the ventricles independent of atrial or AV nodal conduction.

VT storm is considered three or more separate episodes of sustained VT within 24 h, each requiring termination by an intervention.^{262,463}

VT morphologies

Monomorphic VT has a similar QRS configuration from beat to beat (Figure 1A). Some variability in QRS morphology at initiation is not uncommon, followed by stabilization of the QRS morphology.

Multiple monomorphic VTs: refers to more than one morphologically distinct monomorphic VT, occurring as different episodes or induced at different times.

Polymorphic VT has a continuously changing QRS configuration from beat to beat indicating a changing ventricular activation sequence (Figure 1C).

Pleomorphic VT has more than one morphologically distinct QRS complex occurring during the same episode of VT, but the QRS is not continuously changing (Figure 1B).

Right and left bundle branch block-like—VT configurations: terms used to describe the dominant deflection in V1, with a dominant R-wave described as 'right bundle branch block-like' and a dominant S-wave as 'left bundle branch block-like' configurations. This terminology is potentially misleading as the VT may not show features characteristic of the same bundle branch block-like morphology in other leads.

Unmappable VT does not allow interrogation of multiple sites to define the activation sequence or perform entrainment mapping; this may be due to: haemodynamic intolerance that necessitates immediate VT termination, spontaneous or pacing-induced transition to other morphologies of VT, or repeated termination during mapping.

Ventricular flutter is a term that has been applied to rapid VT that has a sinusoidal QRS configuration that prevents identification of the QRS morphology. It is preferable to avoid this term, in favour of monomorphic VT with indeterminate QRS morphology.

Mechanisms

Scar-related reentry describes arrhythmias that have characteristics of reentry and originates from an area of myocardial scar identified from electrogram characteristics or myocardial imaging. Large reentry circuits that can be defined over several centimetres are commonly referred to as 'macroreentry'.

Focal VT has a point source of earliest ventricular activation with a spread of activation away in all directions from that site. The mechanism can be automaticity, triggered activity, or microreentry.

associated with areas of scar, designated as *scar-related reentry* (Table 1). Evidence supporting reentry includes initiation and termination by programmed stimulation (although this does not exclude triggered activity), demonstrable entrainment or resetting with fusion, and continuous electrical activity that cannot be dissociated from VT by extrastimuli. Myocardial scar is identified from: low-voltage regions on ventricular voltage maps, areas with fractionated electrograms, unexcitability during pace mapping, evidence of scar on myocardial imaging, or from an area of known surgical incision. Prior MI is the most common

cause, but scar-related VT also occurs in other myocardial diseases including arrhythmogenic right ventricular cardiomyopathy (ARVC), sarcoidosis, Chagas' disease, dilated cardiomyopathy, and after cardiac surgery for congenital heart disease (particularly Tetralogy of Fallot) or valve replacement.²⁰⁻³⁰

The substrate supporting scar-related reentry is characterized by (i) regions of slow conduction, (ii) unidirectional conduction block at some point in the reentry path that allows initiation of reentry, and (iii) areas of conduction block that often define parts of the reentry path.³¹⁻³⁴ Ven-

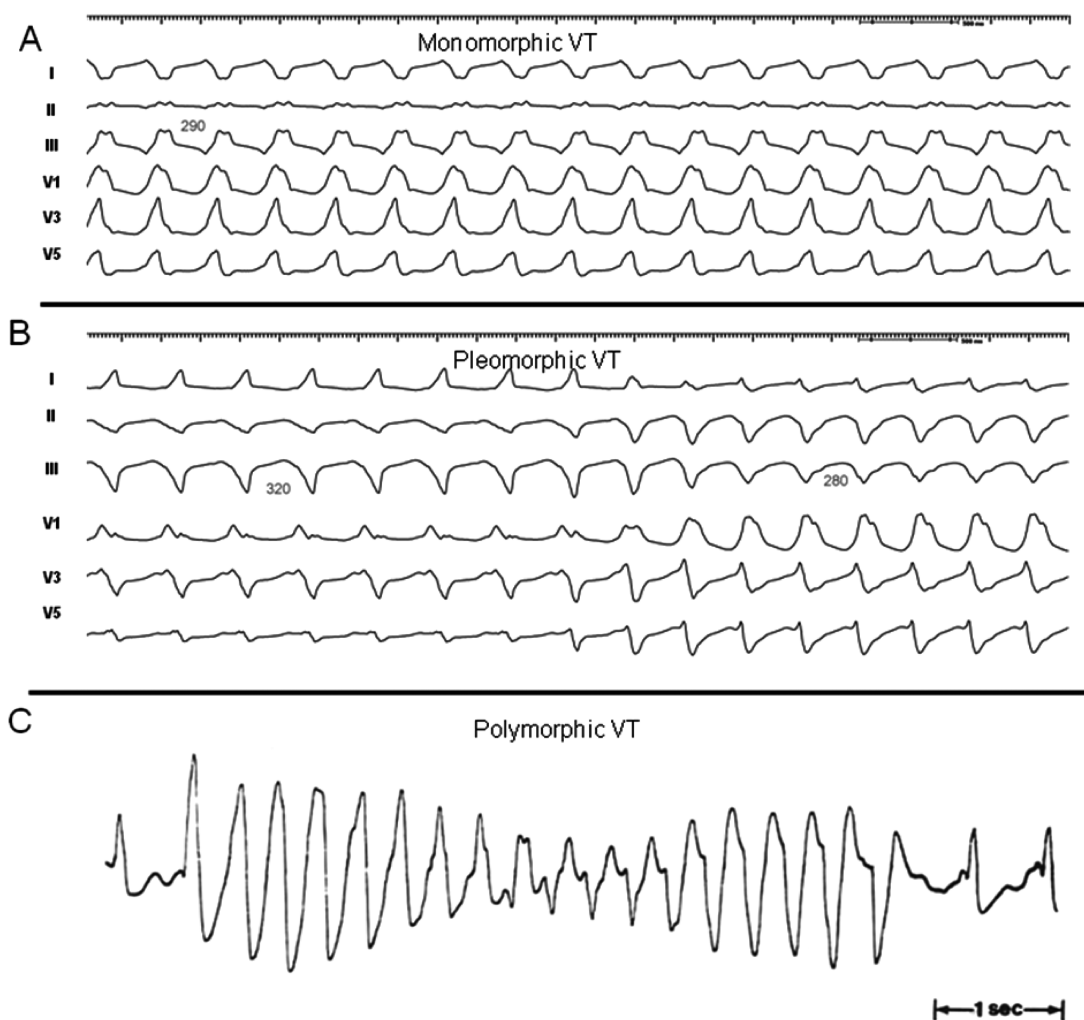


Figure 1 Monomorphic (A), pleomorphic (B) and polymorphic (C) VTs.

tricular tachycardia after MI has been extensively studied in canine models and in humans.³⁵⁻⁴¹ Reentry occurs through surviving muscle bundles, commonly located in the subendocardium, but that can also occur in the mid-myocardium and epicardium. There is evidence of ongoing ion channel remodelling within scar, at least early after MI, resulting in regional reductions in I_{Na} and I_{Ca} ,⁴² although late after infarction action potential characteristics of surviving myocytes can be near normal.³⁵ Coupling between myocyte bundles and myocytes is reduced by increased collagen and connective tissue, diminished gap junction density, and alterations in gap junction distribution, composition, and function.⁴³ Surviving fibres can be connected side to side in regions where the collagenous sheaths are interrupted, resulting in a zig-zag pattern of transverse conduction along a pathway lengthened by branching and merging bundles of surviving myocytes.^{34,35,44,45} The pattern of fibrosis may be important in determining the degree of conduction delay; patchy fibrosis between strands of surviving muscle produces greater delay than diffuse fibrosis.^{31,46} These aspects of scar remodelling contribute to the formation of channels

and regions where conduction time is prolonged, facilitating reentry.⁴⁷

Unidirectional conduction block may occur after a properly timed extra-beat and is probably functional rather than fixed in most instances (see below).^{38,48,49} Regions of conduction block can be anatomically fixed such that they are present during tachycardia and sinus rhythm; dense, non-excitable fibrosis or valve annuli create these types of anatomical boundaries for reentry (Figure 2).⁵⁰⁻⁵³ Alternatively, conduction block can be functional and present only during tachycardia when the refractory period of the tissue exceeds the tachycardia cycle length, or is maintained by collision of excitation waves (Figure 2D).^{33,38,48,49,54} Functional conduction block can occur in figure of eight type of reentry circuits.^{40,45,55,60}

Many reentry circuits contain a protected isthmus or channel of variable length, isolated by arcs of conduction block.^{30,35,54-64} Depolarization of the small mass of tissue in a channel is not detectable in the body surface ECG; thus catheter-recorded electrograms in this region are manifest during 'electrical diastole' between QRS complexes. At the

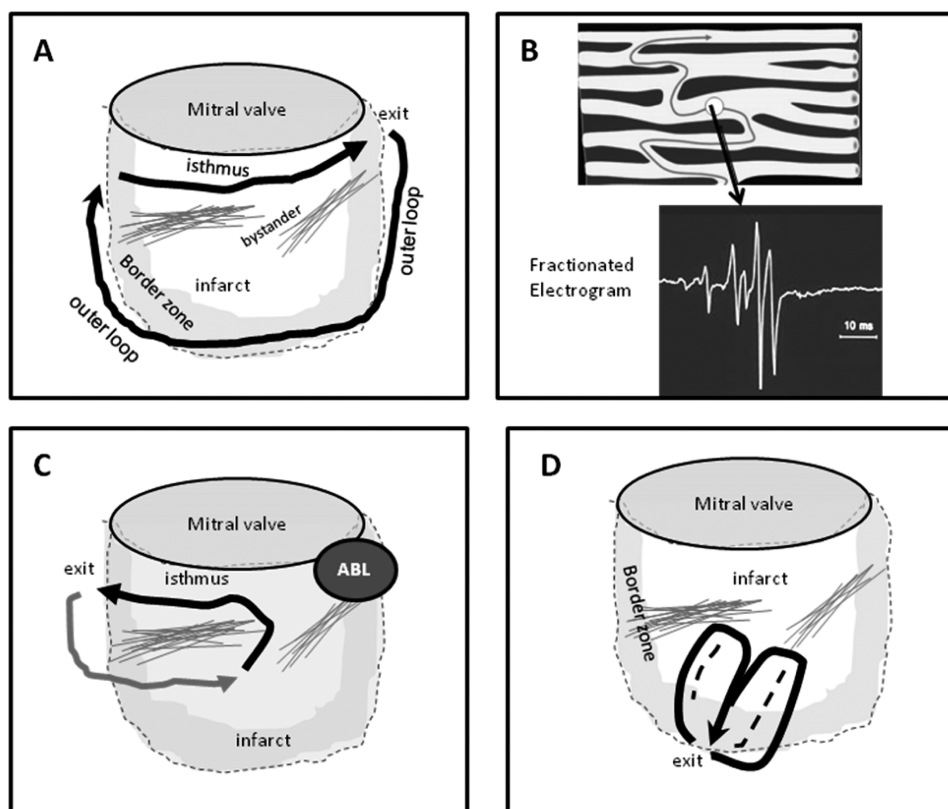


Figure 2 Theoretical reentry circuits related to an inferior wall infarct scar are shown. (A) A large inferior wall infarct designated by the dashed line and shaded border zone. Areas of dense fibrosis define an isthmus along the mitral annulus. A large reentry circuit uses this isthmus and exits at the lateral aspect of the scar. An outer loop propagates along the border to re-enter the isthmus at the medial aspect. Note that this circuit could potentially revolve in the opposite direction as well (not shown) producing VT with a different QRS morphology. Bystander regions are present as well. (B) The anatomic basis of slow conduction that facilitates reentry is shown. Fibrosis (dark bands) separates muscle bundles creates circuitous paths for conduction. Electrograms from these regions have a fractionated appearance indicating asynchronous activation of myocyte bundles. (C) The effect of ablation (Abl) at the exit for the VT. VT-1 is interrupted but other potential reentry paths are present that can allow other VTs. (D) A functionally defined figure-eight type of reentry circuit, in which the central isthmus is defined by functional block (dashed lines).

exit from the channel, the wavefront propagates across the ventricles establishing the QRS complex. To return to the entrance to the channel, the reentry wavefront may propagate along the border of the scar in an outer loop or may propagate through the scar in an inner loop. Multiple potential loops may be present. There are a variety of potential reentry circuit configurations and locations that vary from patient to patient.^{33,54,56-58} Often VT isthmus sites span a few centimetres at the border zone of scars.^{54,56,58,59} Larger macroreentry circuits spanning several centimetres can also be encountered.^{54,57,58} In cardiomyopathies and inferior wall infarcts, reentry circuits are often located adjacent to a valve annulus, suggesting that the valve annulus often helps to define a reentry path.^{54,55,60,61,66}

Multiple VT morphologies are usually inducible in the same patient, often related to multiple reentry circuits. Two different reentry circuits may share the same exit with functional block changing the QRS morphology, may have the same or similar common isthmus with a different exit, or may have two different isthmuses in different areas of the same scar or in different scars (Figure 2).^{55,56,58,62} The presence of multiple potential reentry circuit paths and the anatomic complexity of scars that support reentry compli-

cate mapping and ablation. It can be difficult to distinguish bystander regions that are not part of the reentry circuit from a critical isthmus.^{30,63} A bystander region for one VT may participate in a different VT (Figure 2). Further complicating assessment is the potential three-dimensional configuration of circuits, which can involve the endocardium, epicardium, or mid-myocardium.^{33,35,38,56}

It is possible that other reentry mechanisms cause some VTs. Spiral wave reentry can be induced in excitable tissue in the absence of tissue discontinuities and could cause ventricular fibrillation (VF) or polymorphic VT (PMVT); anchoring to a discontinuity or region of slow conduction could theoretically cause monomorphic VT.^{34,64} Whether this type of functional reentry causes VT in humans and whether it would be susceptible to ablation is not known.

Reentry in the Purkinje system

Reentry within the Purkinje fibres and the specialized conduction system causes ~5% of all SMVTs encountered in patients undergoing catheter ablation. Macroreentry through the bundle branches occurs in patients with slowed conduction through the His-Purkinje system and is usually associated with severe left ventricular (LV) dysfunction due to

dilated cardiomyopathy, valvular heart disease, and less often ischaemic heart disease (see below).^{65,67,68,70}

Left ventricular intrafascicular verapamil-sensitive VT occurs in patients without structural heart disease. The mechanism is reentry that appears to involve a portion of the LV Purkinje fibres, most often in the region of the left posterior fascicle, giving rise to a characteristic right bundle branch block (RBBB) superior axis QRS configuration and a QRS duration that is only slightly prolonged.^{69,70}

Electrophysiological basis for catheter ablation

The mechanism of VT is a key determinant for selection of mapping strategies to identify ablation target sites. For idiopathic VT, the focal origin or critical portion of the reentry path is usually contained in a very small area such that discrete lesions can abolish VT; therefore, mapping targets a precise region. For scar-related VTs, ablation is aimed at transecting the critical VT isthmus. Ventricular tachycardia isthmuses may be narrow, allowing a discrete lesion to abolish VT, or broad, requiring larger ablation areas. In addition, in patients with unmappable VTs and multiple VTs, larger ablation areas targeting putative critical reentry sites, often in or near the border zone of scars, are often employed. In post-MI VT, most reentry circuit isthmuses can be transected using an endocardial approach.^{50,52,54,57,59,62,71-73} However, critical reentry circuit sites are intramural or subepicardial in some patients; these locations are common in some cardiomyopathies.^{71,74,75}

In Purkinje reentry VT, specialized conduction fibres that are part of the reentry path are targeted for ablation.^{17,65,67,68}

III. Indications for catheter ablation of ventricular tachycardia

Selection of catheter ablation for an individual patient should consider risks and benefits that are determined by patient characteristics, as well as the availability of appropriate facilities with technical expertise. In patients with structural heart disease, episodes of sustained VT are a marker for increased mortality and reduce quality of life in patients who have implanted defibrillators and structural heart disease.⁷⁶⁻⁸⁰ Antiarrhythmic medications can reduce the frequency of ICD therapies, but have disappointing efficacy and side effects.⁸¹⁻⁸³ Advances in technology and understanding of VT substrates now allow ablation of multiple and unstable VTs with acceptable safety and efficacy, even in patients with advanced heart disease. In the past, ablation was often not considered until pharmacological options had been exhausted, often after the patient had suffered substantial morbidity from recurrent episodes of VT and ICD shocks. There was consensus among the task force members that catheter ablation for VT should generally be considered early in the treatment of patients with recurrent VT. General recommendations for the use of catheter ablation are summarized in Table 2. More detailed information regarding risks and benefits for specific types of VT and in specific types of heart disease is provided in sections below. It should be recognized that the database for

Table 2 Indications for catheter ablation of ventricular tachycardia

Patients with structural heart disease (including prior MI, dilated cardiomyopathy, ARVC/D)

Catheter ablation of VT is recommended

1. for symptomatic sustained monomorphic VT (SMVT), including VT terminated by an ICD, that recurs despite antiarrhythmic drug therapy or when antiarrhythmic drugs are not tolerated or not desired;*
2. for control of incessant SMVT or VT storm that is not due to a transient reversible cause;
3. for patients with frequent PVCs, NSVTs, or VT that is presumed to cause ventricular dysfunction;
4. for bundle branch reentrant or interfascicular VTs;
5. for recurrent sustained polymorphic VT and VF that is refractory to antiarrhythmic therapy when there is a suspected trigger that can be targeted for ablation.

Catheter ablation should be considered

1. in patients who have one or more episodes of SMVT despite therapy with one of more Class I or III antiarrhythmic drugs;*
2. in patients with recurrent SMVT due to prior MI who have LV ejection fraction >0.30 and expectation for 1 year of survival, and is an acceptable alternative to amiodarone therapy;*
3. in patients with haemodynamically tolerated SMVT due to prior MI who have reasonably preserved LV ejection fraction (>0.35) even if they have not failed antiarrhythmic drug therapy.*

Patients without structural heart disease

Catheter ablation of VT is recommended for patients with idiopathic VT

1. for monomorphic VT that is causing severe symptoms.
2. for monomorphic VT when antiarrhythmic drugs are not effective, not tolerated, or not desired.
3. for recurrent sustained polymorphic VT and VF (electrical storm) that is refractory to antiarrhythmic therapy when there is a suspected trigger that can be targeted for ablation.

VT catheter ablation is contra-indicated

1. in the presence of a mobile ventricular thrombus (epicardial ablation may be considered);
2. for asymptomatic PVCs and/or NSVT that are not suspected of causing or contributing to ventricular dysfunction;
3. for VT due to transient, reversible causes, such as acute ischaemia, hyperkalaemia, or drug-induced torsade de pointes.

ARVC/D, arrhythmogenic right ventricular cardiomyopathy/dysplasia; ICD, implantable cardioverter defibrillator; MI, myocardial infarction; VT, ventricular tachycardia; VF, ventricular fibrillation.

*This recommendation for ablation stands regardless of whether VT is stable or unstable, or multiple VTs are present.

these consensus recommendations consists largely of uncontrolled trials and single-centre reports as summarized in the discussion of individual diseases below.

IV. Technical aspects

Technologies for mapping and ablation

Technological advances have been critical to the development of the field and will continue to play an important role in improving outcomes. The evaluation of new technologies

has generally been based on uncontrolled series. There is limited head-to-head comparison of different technologies. Although new technologies generally increase the cost of a procedure when they are introduced, the costs may be justified if they improve outcomes.

The process of evaluation and adoption of new technologies for clinical practice varies from country to country. In this document, the assessment of technologies is based on review of the literature and consensus of the task force. Individual technologies may not have been approved specifically for catheter ablation of VT. It is important for the electrophysiologist performing these procedures to recognize the value and limitations of each mapping system for their effective use. As the field continues to evolve, adoption of new technologies should be based on well-designed clinical trials.

Mapping systems

Mapping systems that create chamber geometry and display the ablation catheter position are often helpful in ablation of VT in structural heart disease and can be useful in selected patients with idiopathic VT.

Electroanatomic mapping systems

Electroanatomic mapping (EAM) refers to point by point contact mapping combined with the ability to display the location of each mapping point in three-dimensional space. This provides the opportunity to record intracardiac electrical activation in relation to anatomical location in a cardiac chamber of interest. Electroanatomic mapping systems integrate three main functions: (i) non-fluoroscopic localization of the ablation catheter within the heart; (ii) display of electrogram characteristics, most commonly activation time or voltage, in relation to anatomic position; and (iii) integration of electroanatomic information with three-dimensional images of the heart obtained from point by point sampling, intracardiac ultrasound, computed tomography (CT), or magnetic resonance imaging (MRI).

In patients with scar-related VTs, EAM systems are useful. In patients with idiopathic VTs, EAM systems can be useful, but are not required and are utilized by approximately half of the task force members.

One system utilizes low-level electromagnetic fields emanating from three separate coils beneath the patient that are measured from a location sensor embedded in the tip of the mapping catheter.⁸⁴ This allows a three-dimensional reconstruction of the chamber of interest and colour-coded display of various electrophysiological parameters for endocardial or epicardial mapping.^{54,73,85-87} An alternative technology determines electrode position based on the measurement of a high-frequency current emitted by three pairs of orthogonally placed skin patches.^{62,88,89} Recently, intracardiac echocardiography (ICE) has been incorporated into EAM.⁹⁰ The ICE probe, equipped with a location sensor and tracked by the mapping system, allows reconstruction of a three-dimensional shell of the chambers of interest before

mapping and may help define irregular anatomic features, such as papillary muscles.⁹⁰

The ability to continuously monitor catheter position without fluoroscopy is expected to reduce fluoroscopy exposure. Electroanatomic mapping systems allow activation mapping that has been used to support catheter ablation of idiopathic focal and reentrant VTs originating in the RV or LV, and/or aortic cusps.⁹¹⁻⁹⁴ Electroanatomic mapping systems are used extensively in patients with VTs due to structural heart disease.^{28,53,54,59,73,85-87,95-107} Often the system is used without performing detailed activation maps, but to obtain an anatomical shell and enable annotation of mapping points of interest, as may be determined based on entrainment mapping or pace mapping. Combining anatomy with plots of electrogram amplitude in 'voltage maps' helps identify areas of ventricular scar, an innovation that was important for the development of substrate mapping (see below).⁷³

There are a number of limitations of these systems. Cardiac and respiratory motion reduce anatomic accuracy. Patient movement relative to the location signal or reference sources invalidates the anatomic maps and can be a major problem when procedures are done with sedation rather than general anaesthesia. Algorithms for anatomic reconstruction differ between systems and likely have different weaknesses. Data are acquired point by point, such that a stable tachycardia or haemodynamic support is usually required for the definition of a complete activation sequence. Point by point mapping is a tedious process that requires considerable skill with catheter manipulation. Incorporation of multiple mapping catheters and electrodes may facilitate spatial sampling.^{108,109}

Multielectrode arrays

Mapping systems that allow for multielectrode mapping are an alternative to point by point sampling that can facilitate reconstruction of the activation sequence and identification of abnormal areas. There are currently two different strategies that allow multielectrode mapping.

A basket-shaped catheter composed of multiple thin splines, each of which has multiple electrodes distributed throughout the length of the spline that can be advanced through a long introducer sheath into the ventricle, has been described.^{110,111} In addition to recording the activation sequence, pace mapping can be performed through the electrodes that are in contact with the endocardium.¹¹² Limitations include mechanical trauma that can terminate VT or induce ectopic beats, incomplete, irregular spatial sampling because the splines do not deploy uniformly and some of the electrodes are often not in contact with myocardium. The splines may interfere with manipulation of an ablation catheter. The potential for clots to form on the splines necessitates careful attention to anticoagulation during the procedure. Small case series and anecdotal reports describe their use to determine ventricular activation sequence during sinus rhythm and during VT in patients with scar-related VTs^{110,111} and to guide ablation of idiopathic RVOT

VT.^{112,113} Other multielectrode catheters are available, but have not been evaluated for guiding VT ablation.^{108,109} These multielectrode arrays (MEAs) that allow contact mapping can be useful in selected patients, but are generally not used by the task force members.

A *non-contact mapping system* consists of a catheter with an MEA of 64 unipolar electrodes over an inflatable balloon.¹¹⁴⁻¹¹⁶ The MEA measures the potential generated by far-field electrograms and also detects the location of a roving mapping catheter. Three-dimensional endocardial geometry is created by dragging the roving catheter around the ventricle. From the sampled far-field potentials and the measured distance between the array and the endocardium, an 'inverse solution' is calculated for the potentials at >3000 points on the endocardial surface to create 'virtual unipolar electrograms'. The virtual electrograms agree with electrograms obtained by contact mapping provided that the endocardial surface of interest is within 4 cm from the centre of the MEA balloon.^{114,115,117}

The system is best suited for activation mapping. In scar-related VTs, an endocardial exit region is identified in >90% of cases, and a portion of the diastolic pathway can be delineated in some.^{116,118,119} Because single beat activation can be assessed, data can be acquired from non-sustained, poorly tolerated, or pleomorphic VTs.

An understanding of the limitations is important to avoid errors in mapping and interpretation of mapping data. Care has to be taken to confirm that the virtual electrogram is related to local activation and not baseline drift or repolarization. Because accuracy decreases as the distance between the MEA and endocardium increases, it should be used with caution in large ventricles. Methods to detect scar based on characteristics of virtual electrograms are under investigation, but may be more difficult to achieve than with contact mapping.^{117,120-122} Displacement of the MEA after creation of endocardial geometry invalidates subsequent mapping data. At present, detection and display of activation from two adjacent structures, such as the papillary muscle and subjacent myocardium, is problematic. The potential for thrombus formation on the MEA requires careful attention to anticoagulation, maintaining an activated clotting time (ACT) >300 s is recommended. The mapping sheath is 9F in diameter; femoral haematomas and pseudoaneurysms are the most frequently encountered complications.

Single-centre case series and case reports have shown that the system can be used to guide catheter ablation of VT in patients with idiopathic VT¹²³⁻¹²⁵ and scar-related VTs due to arrhythmogenic right ventricular dysplasia (ARVD),¹²⁶ congenital heart disease,¹²⁷ cardiomyopathy, and MI.^{116,118,119,128,129}

Robotic navigation

Catheter-based ablation of VT places significant demands on the skill and experience of the electrophysiologist. Remote, robotic catheter manipulation seeks to achieve precise and stable catheter navigation, reduced radiation exposure for patient and operator, and shorter procedure times. This

concept is appealing for the operator, for whom it may reduce radiation exposure and the chronic physical stress related to prolonged use of protective lead aprons. Two technologies are available, a robotic controlled sheath system^{130,131} and a magnetic navigation system that is combined with an EAM system.¹³²⁻¹³⁴ Neither is FDA-approved for ablation of VT. The large diameter and relatively short reach of the robotically controlled sheath limit applicability for ventricular mapping and no clinical experience with VT ablation has been published. Small case series reporting the use of the magnetic navigation system indicate that point by point mapping can be accomplished with very short fluoroscopy exposure times.^{113,135-137} At present, studies are not available to demonstrate that either of these systems shortens procedure times or improves efficacy or safety of VT ablation. Such studies are needed to determine their role in catheter ablation of VT and to justify their expense. The present reported experience is not sufficient to form a conclusion as to the utility of these technologies for VT ablation.

Imaging

An understanding of anatomy is important for mapping and ablation. There is increasing interest in cardiac imaging to identify anatomic correlates and obstacles to ablation of VT. There are no trial data to show that sophisticated imaging improves ablation outcomes, but there is substantial experience with pre- and post-procedure echocardiographic imaging, which is widely accepted in clinical practice.

Pre-procedural imaging is used to identify ventricular thrombi that could increase the risk of endocardial mapping (see below), and identify regions of wall motion abnormalities that may contain the potential VT substrate. Because defining the presence and severity of underlying heart disease is an important part of the clinical evaluation of any patient with ventricular arrhythmias, almost all patients should have some type of pre-procedural imaging, such as echocardiography, ventriculography, nuclear imaging, and/or MRI or CT imaging.

When scar-related VT is suspected, imaging can be used to characterize the location/extent of the myocardial scar that is likely to contain the VT substrate.^{97,138-140} Magnetic resonance imaging using delayed Gd enhancement pulse sequences can be used to identify scar with good spatial resolution. Magnetic resonance imaging is limited in the VT population because many patients have implanted permanent pacemakers or defibrillators. Many institutions prohibit the use of MRI in these patients, although feasibility of imaging with a 1.5 T magnet in patients with pacemakers or defibrillators (after changing the pacing mode to either 'demand' only or 'asynchronous' for pacemaker-dependent patients, and disabling magnet response and tachyarrhythmia functions) has been demonstrated.¹⁴¹⁻¹⁴³ 'Delayed enhancement' CT imaging has been investigated for visualizing scarred myocardium, but the reproducibility and true sensitivity of this imaging modality are still unclear.^{144,145} Positron emission tomography-CT (PET-CT) can provide scar location information, albeit with less spatial accuracy

than MRI.^{144,145} It is likely that further advances in imaging technologies will allow more precise imaging of myocardial scar in the future and further studies will be required to determine their utility for facilitating VT ablation.^{146,147}

Intracardiac echocardiography is increasingly employed during procedures. It can be used to define three-dimensional ventricular chamber geometries and to observe contact between the catheter tip and underlying tissue that can be helpful during ablation on irregular structures such as papillary muscles.¹⁴⁸⁻¹⁵⁰ Intracardiac echocardiography has been used to visualize the proximity of the ablation catheter tip to an adjacent coronary artery when ablating in the left ventricular outflow tract (LVOT) or aortic valve cusps, but requires skill and experience in obtaining and interpreting ICE images.^{151,152} Coronary angiography to allow fluoroscopic visualization of coronary anatomy is presently more commonly employed for this purpose.

Another emerging intra-procedural imaging strategy is the incorporation of pre-acquired volumetric MRI, CT, or PET-CT images into mapping systems to help to detect the arrhythmia substrate as well as anatomic obstacles to ablation, such as epicardial fat.^{145,147,153} The clinical value of these methods has not yet been demonstrated.

Post-procedural imaging is indicated when there is haemodynamic deterioration or instability. Most commonly, imaging with transthoracic echocardiography is performed to assess the presence of pericardial effusion and tamponade, valve injury, or deterioration of ventricular function.

Energy sources for ablation

Radiofrequency energy is most commonly used for ablation and is relatively simple and effective. Ablation of idiopathic VTs can often be accomplished with relatively small lesions created by RF applied to a solid electrode 4 or 5 mm in length. Ablation of scar-related VTs can require ablation of large areas and regions deep to the endocardium that is facilitated by the use of larger electrodes or irrigated electrodes. There is consensus that irrigated RF electrodes are preferred for ablation of scar-related VT. There are no randomized trials comparing different RF ablation methods for VT ablation. There is limited experience with other energy sources.

Standard radiofrequency ablation

Thermal injury produced by RF ablation is due to resistive heating of tissue with some conductive heating of the surrounding tissue.¹⁵⁴⁻¹⁵⁶ Permanent tissue injury occurs at temperatures exceeding 49°C. The RF electrode heats as a consequence of its contact with the tissue. Heating is limited by coagulation of proteins on the electrode that occurs at electrode temperatures exceeding 70°C. Circulating blood cools the electrode such that measured catheter electrode temperature is less than tissue temperature. Tissue heating is indicated by the increase in electrode temperature and fall in measured impedance during ablation.

For endocardial ablation of idiopathic VT, standard solid 4 or 5 mm electrode RF ablation catheters are usually

adequate. In addition to RF power and duration, which are controlled by the operator, the effectiveness of RF lesion creation depends on electrode-tissue contact and the extent of cooling from circulating blood flow which are variable and not known by the operator.¹⁵⁴⁻¹⁵⁶ The optimal method of energy application has not been defined and a variety of different approaches to energy titration can be successful. Energy applications should be titrated to that required to eliminate the arrhythmia and to avoid excessive tissue damage. Power of 30–50 W is typically applied in the temperature control mode and titrated to an electrode temperature of 55–70°C or an impedance fall of 10–15 ohm. Careful attention to temperature, impedance, and power is important. Brisk heating at low power (e.g. <15 W) may indicate the location of the electrode in a low flow area and limited lesion creation, despite electrode heating. A brisk fall in impedance of >18 ohm may indicate substantial tissue heating and may warrant a reduction in power to avoid steam pops (see below), even though measured temperature is <60°C.^{155,156}

Compared with standard solid 4 or 5 mm length electrodes, increasing ablation electrode size (typically to 8 or 10 mm) allows greater energy delivery because the greater surface area of the electrode increases electrode cooling from circulating blood.^{155,156} Although this is relatively simple and avoids the need for irrigation pumps, there are disadvantages of large electrodes. Greater power is required for lesion creation. There is a greater disparity in temperatures across the surface of the large electrode such that hot regions can lead to coagulum formation despite relatively low temperatures recorded from the electrode. Increasing the size of the electrode reduces the spatial resolution of mapping.

Irrigated radiofrequency ablation

Irrigation of the ablation electrode allows more power to be applied before temperature increases to the point of coagulum formation, increasing the size of RF lesions that can be created and facilitating interruption of scar-related ventricular reentry.¹⁵⁷ Two different types of electrode irrigation are available. An internal irrigation catheter circulates 5% dextrose solution at room temperature in a closed loop through the tip electrode. Open irrigation catheters infuse saline that emerges through pores in the ablation electrode, cooling the electrode and providing some cooling of the tissue-electrode interface. There are no trials directly comparing open vs. closed irrigation for RF ablation of VT. In experimental preparations, external irrigation has a lower risk of coagulum and thrombus formation, possibly due to more effective electrode-tissue interface cooling, when compared with internal irrigation.¹⁵⁸ A low risk of coagulum formation with open irrigation is supported by the absence of thromboembolic complications in three multicentre trials involving 353 patients.^{102,105,106}

External irrigation does result in intravascular saline administration, amounting to a median of 1 L of saline in a recent trial,¹⁰⁵ which can potentially cause pulmonary oe-

dema. Careful monitoring of fluid balance is required and a urinary catheter and diuretic administration may be needed during the procedure. Internal irrigation catheters or large tip catheters should be considered if intravascular volume administration will be difficult to manage, as in patients with renal failure and/or severe heart failure.

Electrode irrigation increases the disparity between tissue temperatures and temperatures recorded from within the electrode.¹⁵⁸ If tissue temperatures exceed 100°C, an explosion of steam within the tissue can occur often with an audible 'pop'.¹⁵⁸ These pops can cause perforation.¹⁵⁹ This risk may be greater in thin-walled structures such as the RV and atria. During ablation in areas of scar, pops are usually not associated with perforation.¹⁵⁹ Cardiac tamponade has been reported in 1% of patients in multicentre trials.^{102,105,106,160} In animal models of atrial ablation, pops are more likely to occur when electrode temperature exceeds 40°C, particularly if power is >40 W, and are often associated with only a small impedance rise, dislocation of the catheter, and a sudden drop in electrode temperature.^{161,162} It has also been suggested that the risk of perforation is greater if the electrode is oriented perpendicular to the tissue, rather than when it is parallel in orientation. In a retrospective study of RF ablation with external irrigation at 30 mL/min for VT ablation, steam pops occurred in 1.5% of 4107 RF ablation lesions.¹⁵⁹ Tamponade occurred following 1 of the 62 pops (2%); this RF application was at the free wall of the RV. Applications with steam pops had greater impedance falls (22 ± 7 vs. 18 ± 8 ohm) and greater maximum power (45 ± 5 vs. 43 ± 6 W), but did not differ in maximum catheter tip temperature ($40 \pm 4^\circ\text{C}$ in both groups). The magnitude of decrease in impedance during RF was the best predictor of a pop, with 80% of pops occurring after impedance had decreased by >18 ohm.

The optimal parameters to guide power titration for irrigated RF ablation are not completely defined. The greatest experience is with the 3.5 mm electrode with external irrigation at 10–25 mL/min for power up to 30 W and 30 mL/min for power of >30 W. For endocardial ablation, initiation of RF current at 30–35 W and increasing power to achieve an impedance fall of 10–15 ohm while maintaining electrode temperature <40–45°C is reasonable. The method employed should also consider the risks of ablation at the site. Lower power should be considered at sites where perforation is a risk, such as the free wall of the RV and within venous structures or in the great vessels.^{163,164} Other irrigated RF systems are in development, and specific operating parameters are likely to vary with a particular system.

Irrigation may be especially important for epicardial RF ablation.^{86,164–166} Although the risk of embolism due to char formation does not exist for epicardial ablation, the absence of electrode cooling from circulating blood markedly limits energy delivery. To increase the depth of epicardial lesion formation, irrigation is necessary. Internally irrigated catheters can be effective. External irrigation infuses saline into the pericardium, necessitating aspiration during the procedure (see below). The optimal infusion rates for epicardial irrigated ab-

lation have not yet been defined, but successful ablation has been performed using irrigation at rates ranging from 2 to 30 cc/min. Irrigation is not needed during mapping.

Irrigated RF ablation has been reported in four multicentre trials and is preferred for ablation of scar-related VT.^{86,102,105,106,160} Some task force members prefer external irrigation, with careful power limitation and titration, for ablation of LV idiopathic VT in the hope of reducing risk of thrombus, although this benefit is not proven.

Other energy sources

Cryoablation catheters are available for clinical use, but there is no compelling data that these catheters improve lesion depth over irrigated RF ablation catheters. Animal data suggest that coronary artery injury is less likely with cryoablation than RF ablation when a coronary artery is close to the ablation target.^{167,168} Feasibility of cryoablation has been demonstrated in small case series and reports in selected clinical situations such as during epicardial ablation near a coronary artery or during ablation from within a coronary vein (which is typically near a coronary artery) and in children.^{164,169}

Inability to create a sufficiently deep lesion to ablate VT is an important cause of ablation failure and can occur when critical portions of the reentry circuit are intramural or epicardial, when epicardial access cannot be achieved. Animal studies have shown that laser, ultrasound, microwave, or intramural irrigated needle RF ablation can produce deep lesions (and the first three have been employed for surgical ablation of VT), but they are not clinically available for catheter ablation.^{170–175}

Anticoagulation

Intravascular insertion and manipulation of catheters, creation of ablation lesions, activation of coagulation factors, and potential disruption of atherosclerotic plaques contribute to a risk of thromboembolism during and after catheter ablation.^{176,177} The risk likely varies with the type and site of ablation, and patient factors that influence the tendency for thromboembolism. Patients with structural heart disease undergoing left heart catheterization have a risk of stroke or thromboembolism of ~1%.^{72,105,119,160,178–186} There are no data comparing different approaches to anticoagulation before, during, or after the procedure. Antithrombotic measures are recommended for all procedures involving left heart catheterization.

Recommendations for anticoagulation

The guidelines for anticoagulation management should be followed if a patient has atrial fibrillation and cardioversion may occur during the ablation procedure.

Right heart procedures that do not involve placement of a catheter into the left ventricle or atrium

During the procedure, systemic anticoagulation with heparin is not necessary unless other factors are present that increase the risk for thromboembolic complications. Some laboratories routinely anticoagulate with heparin due to con-

cern for deep venous thrombosis and pulmonary emboli. Anticoagulation during the procedure may be considered, particularly for long procedures, when multiple venous catheters or when extensive ablation is required. Anticoagulation is warranted for patients with a history of prior venous thromboemboli, and/or who have known risk factors for thrombosis (e.g. Factor V Leiden) or have right to left intracardiac shunts that pose a risk of paradoxical embolism. Following the procedure, long-term anticoagulation is not required. Some centres administer aspirin 75–325 mg daily for 3–12 weeks.

Left heart procedures in the absence of structural heart disease

Anticoagulation therapy prior to the intervention is not required. During the procedure, systemic anticoagulation with intravenous heparin is recommended as for patients with structural heart disease. Ventricular tachycardia in these patients is usually ablated with a small number of focal lesions. After ablation, anticoagulation is not required. Some laboratories administer aspirin 75–325 mg for 4–8 weeks. Anticoagulation with warfarin may be considered for patients who receive extensive areas of ablation or who are at increased risk of thromboemboli.

Left heart procedures in patients with structural heart disease

Imaging to assess the presence of an LV thrombus is warranted prior to endocardial LV mapping. A mobile LV thrombus is a contraindication to LV endocardial mapping and ablation. Evidence of laminated thrombus is not a contraindication to ablation; some laboratories prefer to anticoagulate with warfarin for 4–6 weeks prior to elective ablation when laminated thrombus is present. Anticoagulation therapy is not generally necessary prior to the ablation procedure, but is often warranted for other indications in this patient population. Anticoagulation with warfarin may be interrupted 3–5 days before the procedure. Bridging therapy with heparin or low-molecular-weight heparin is dictated by other indications for anticoagulation.

Peri-procedure anticoagulation. After sheath insertion, systemic anticoagulation is warranted. Anticoagulation regimens differ among centres. Some do not administer heparin until it is determined that the aorta can be navigated with the ablation catheter, to preserve the option of performing trans-septal access prior to anticoagulation if vascular access is difficult. The potential use of percutaneous pericardial access is also a consideration (see section on pericardial access). For adults, iv heparin is commonly administered as an initial bolus (empirical dose 5000–10 000 U or 50–100 U/kg) followed by a continuous infusion or intermittent boluses (usually 1000–1500 U/h) to maintain an ACT level of ≥ 250 s with periodic measurement. Greater degrees of anticoagulation may be considered if long vascular sheaths are inserted into the ventricle by retrograde aortic or trans-septal approaches. Some electrode arrays that may be

thrombogenic require an ACT >300 s. Anticoagulation is not needed for epicardial mapping and ablation (see below).

Immediate post-procedure anticoagulation. At the completion of the procedure, anticoagulation with heparin or low molecular weight heparin may be instituted 4–6 h after haemostasis is achieved and continued for 12–48 h or until the target INR is reached when warfarin is administered.

Follow-up anticoagulation. During initial follow-up, anticoagulation is recommended with aspirin (75–325 mg daily) or warfarin for 6–12 weeks. Following extensive ablation over large areas (e.g. several centimetres), anticoagulation with warfarin rather than aspirin is reasonable. Determination of the anticoagulation regimen should consider the extent of ablation, patient factors that influence the risk of thromboembolism, and the risks of anticoagulation. Anticoagulation regimens have not been tested in trials and these regimens are based on consensus. Some centres administer warfarin when LV function is severely depressed. Anticoagulation is not required if only epicardial ablation is performed.

Sedation and analgesia

Mapping and ablation procedures are performed with variable degrees of sedation and analgesia, which depend upon the extent of the procedure and the condition and characteristics of the patient. The purpose of sedation is to minimize anxiety and awareness and to relieve any pain caused by the procedure. The depth of sedation required ranges from minimal to deep and may include general anaesthesia. Assessment of the risks for sedation and anaesthesia must be performed prior to the procedure in order to preemptively plan for patient needs so that the progress of the case is unimpeded. Consultation with an anaesthesiologist is warranted for high-risk patients or those who are likely to require deep sedation and/or general anaesthesia so that haemodynamic stability and respiratory function are maintained at all times. Sedation/analgesia needs to be administered by trained individuals with concomitant monitoring of heart rate, blood pressure, and oxygen saturation.^{188,189} Capnography can be useful because it provides an indication of respiration and cardiac function.^{188–190} Respiratory arrest may escape detection for 30 s or more when only arterial O₂ saturation is monitored.

The level of training required to safely administer intravenous sedation and analgesia has been outlined by the American Society of Anesthesiologists.¹⁸⁸ Personnel must also meet institutional requirements that vary among centres.

Either conscious sedation or general anaesthesia may be used. The best sedation strategy for an individual patient is dependent upon patient age, associated co-morbidities, and targeted arrhythmias. In adults, short-acting benzodiazepines and opioid analgesics are often sufficient to achieve the level of sedation/analgesia necessary to perform a mapping and ablation procedure. Supplementation with short-acting intravenous general anaesthetic agents such as propo-

fol, ketamine, or etomidate may also be helpful. General anaesthesia provides more complete relief of discomfort and has the advantage of avoiding patient movement, thereby facilitating the process of vascular access, epicardial access, and catheter manipulation and ablation. Manipulation of the ventilator cycle may also help to minimize catheter movement during ablation. Placement of an oral airway by a trained anaesthesiologist or supervised registered nurse can also be helpful in reducing respiratory motion in sedated patients.

General anaesthesia is usually required for ablation procedures in children. It is also a safe alternative in adults at risk for airway obstruction, other respiratory compromise and haemodynamic instability, or in high-risk patients with other major co-morbidities. A major disadvantage of general anaesthesia is the potential for suppressing VT inducibility. It is desirable to avoid general anaesthesia and deeper levels of sedation in patients with catecholamine-sensitive VTs, particularly if VT was not inducible at a prior procedure. In children, propofol and isoflurane do not interfere with inducibility of common supraventricular reentrant arrhythmias.^{191,192} One study found no impact of enflurane on VT inducibility in patients with structural heart disease.¹⁹³ Halothane decreased inducibility of VT in a post-infarction dog model.¹⁹⁴ General anaesthesia may cause vasodilation and impair reflex responses to hypotension during induced VT, although this can often be countered with volume administration and vasopressors. If general anaesthesia is used during epicardial mapping and ablation procedures, paralytic agents should be avoided as these may prevent identification of the phrenic nerve by high output pacing.

As an alternative to general anaesthesia throughout the procedure, a deeper level of sedation can be achieved as needed with a drug such as propofol, when sudden movements of the patient need to be prevented in critical situations (epicardial puncture, for example). If short-acting agents are used, the depth of sedation can be reduced when needed to facilitate initiation of VT.

Antiarrhythmic drug management in patients undergoing ablation

Most patients who undergo catheter ablation of VT or VF will have failed prior antiarrhythmic drug therapy because of either drug inefficacy or intolerance. Since catheter ablation of idiopathic VT in the absence of structural heart disease is greatly facilitated by activation mapping during spontaneous or induced VT, antiarrhythmic drugs (including β -blockers) should be discontinued for 4–5 half-lives before the procedure. For patients with poorly tolerated VT, hospitalization may be required for drug discontinuation. After ablation of idiopathic VT, most patients can be discharged without antiarrhythmic drugs, although it may be prudent to gradually taper β -blockers.

In contrast to patients with idiopathic VT, many of those with VT related to significant structural heart disease have received prior treatment with Class III antiarrhythmic drugs

such as sotalol or amiodarone.^{82,83,101,105,160,195} If VT is incessant, catheter ablation is usually performed on an urgent basis, regardless of drug therapy. In addition, intravenous procainamide or amiodarone may slow the rate of VT allowing a haemodynamically unstable VT to become better tolerated and mapping to be performed. These drugs may also convert pleomorphic VTs to a more stable monomorphic VT. However, in order to facilitate the induction and mapping of intermittent VT, Class III or I antiarrhythmic drugs with short elimination half-lives are generally discontinued for 4–5 half-lives prior to catheter ablation. Due to the very prolonged elimination half-life of amiodarone, many patients will undergo catheter ablation of VT while therapeutic effects are present. Thus, the results of catheter ablation must be considered to reflect the combined effects of ablation and amiodarone. There are no trials that address management of amiodarone after ablation and recommendations are based on consensus. Following successful catheter ablation, amiodarone may be discontinued but is often continued at a reduced dose. If Class I or III antiarrhythmic drugs are added or discontinued after ablation, the potential effects of these drugs on the rate of recurrent VT and the defibrillation threshold should be considered for programming of the patient's ICD. Ventricular tachycardia inducibility and cycle length may warrant reassessment several weeks after a change in amiodarone therapy, due to its long half-life. In patients with structural heart disease treated with β -adrenergic blockers, these drugs should usually be continued after ablation.

Risks of catheter ablation

Catheter ablation of VT is a complex intervention often performed in patients with advanced heart disease. There are significant risks that require careful consideration.¹⁹⁶ For the purpose of this document, a major complication is defined as one that leads to prolongation of hospital stay or to another hospitalization, requires additional intervention for treatment, and/or results in significant injury or death. Although serious complications are uncommon during ablation of idiopathic VTs (see below), the incidence of major procedure-related complications reached 8% in a multicentre trial of VT ablation in patients with advanced structural heart disease, with a 3% procedure-related mortality.¹⁶⁰ Mortality is often due to incessant VT, which may simply reflect failure of the procedure to control VT in an ill patient, although a proarrhythmic effect cannot be excluded in some patients. More recently, significant complications have been reported in <5% of patients who underwent prophylactic catheter ablation of post-infarction VT in randomized, multicentre study.¹⁰² It should be recognized that these reports are largely from experienced centres. Some specific complications have been reported only anecdotally and some are particular to epicardial catheter ablation (see below).

Vascular injury

For VT ablation, standard vascular access techniques are used. For LV access, a retrograde transaortic approach is

most commonly employed. In the presence of a mechanical aortic valve or aortic valve disease, an atrial transeptal approach allowing access to the LV through the mitral valve can be considered. This approach can also be useful in patients with peripheral vascular disease to avoid arterial complications of a retrograde aortic approach. Transeptal puncture also has risks, including perforation and embolization. Venous injury may lead to deep venous thrombosis and pulmonary embolism. Femoral haematomas, atrio-ventricular (AV) fistula, and pseudoaneurysms also occur. Significant vascular complications are estimated to occur in ~2% of procedures.^{72,105,119,160,178-186}

Thromboembolism

In 13 published series reporting radio frequency (RF) catheter ablation in a total of 1079 patients, cerebrovascular accidents and transient ischaemic attacks occurred in 1.3% of patients.^{72,105,119,160,178-186} Open irrigated tip ablation has been suggested to reduce the risk of thrombus formation, but marked differences in thromboembolic risk between different ablation methods and with extensive substrate ablation have not been documented based on clinical experience or trials in VT ablation.^{110,161,165}

Air embolism

Use of long sheaths to reach the LV, as with the transeptal approach, is associated with a risk of coronary or cerebral air embolism. Coronary embolism typically involves the right coronary artery and produces ST segment elevation and transient chest pain. Urgent coronary angiography may be required to disintegrate the air bubble. Cerebral air embolism is potentially more serious and may warrant hyperbaric oxygenation.¹⁹⁷

Cardiac tamponade

Cardiac tamponade is reported in ~1% of procedures.^{72,105,119,160,178-186} Mechanical perforation during catheter manipulation or tissue disruption during RF ablation and steam pops are potential causes. The risk is likely to be greater in the free wall of the RV, warranting careful consideration in ablation energy titration. Limiting RF power to achieve impedance decrease of <18 ohm with open irrigation catheters has been suggested.¹⁵⁹

Valve injury

The aortic valve can be damaged during retrograde crossing of the ablation catheter. Entrapment in the mitral or tricuspid valve is unlikely with an ablation catheter; however, it could occur with catheters with multiple splines or circular mapping catheters.

Damage to the conduction system

Atrio-ventricular block can occur when ablating along the interventricular septum and/or when the ablation involves the conduction system; it is often an anticipated complication in these situations. In some patients, mechanical trauma from the catheter induces temporary AV block. The subsequent necessity for ventricular pacing has the potential to aggravate ventricular dysfunction in some patients.

Damage to the coronary arteries

The ostia of the coronary arteries can be injured during attempts for retrograde crossing of the aortic valve or during ablation in the region of coronary cusps. Coronary angiography is recommended prior to ablation in the aortic sinuses to ensure that distance is maintained between the catheter tip and the coronary ostium. Alternatively, ICE could potentially be used for this purpose if sufficient expertise is available.¹⁹⁸ Avoiding high-power applications in the aortic root is prudent.

Myocardial ischaemia

Episodes of induced VT can cause hypotension and myocardial ischaemia that may aggravate ventricular dysfunction.

Heart failure

In patients with LV dysfunction, the additional saline administration from open irrigation catheters increases the risk of acute heart failure. Careful attention to fluid balance and ability to manage fluid administration with diuresis are warranted. Extensive ablation in viable myocardium and repeated VT episodes with hypotension that may cause myocardial ischaemia can lead to heart failure or cardiogenic shock in patients with impaired ventricular function.

In patients with scar-related VT, particularly after MI, heart failure accounts for more than one-third of mortality during follow-up late after ablation and exceeds 10% per year in some studies.^{72,105,119,160,178-186} As noted above, there are a number of complications by which catheter ablation could increase heart failure. Extensive substrate-based ablation has the potential to damage contracting myocardium and this consideration is a reason to attempt to restrict RF ablation lesions to regions identified as scar and the scar border zone when extensive ablation is needed in patients with scar-related VT. Several observations suggest that VT ablation is not a major cause of the heart failure in this patient population. Severely depressed ventricular function and a history of heart failure are common in these patients such that the reported heart failure mortality is in line with expectations for this population. Furthermore, the occurrence of VT is a marker for increased heart failure and mortality in patients with ICDs, suggesting that these patients are at increased risk.^{78,79} Assessment of LV ejection fraction (LVEF) before and after ablation in small series does not suggest an adverse effect.^{73,102,199} Serial echocardiographic assessment of LV function in a randomized trial of substrate-guided ablation did not find evidence of a detrimental effect of ablation on LV function.¹⁰² Despite these reassurances, the frequency with which VT ablation aggravates heart failure is not known. Attention to measures that reduce injury to functioning myocardium, valves, and the conduction system is prudent.

Radiation

As with any ablation procedure, the patient and staff are exposed to the radiation risks associated with fluoroscopy. Attention to measures that reduce radiation exposure is important.^{200,457-460} The use of EAM systems may help

reduce radiation exposure.⁹¹ Remote navigation systems also have the potential to reduce radiation exposure.¹³⁵

V. Ventricular tachycardia in structural heart disease

The most common cause of scar-related VT is a prior MI. The term *non-ischaemic cardiomyopathy* refers to all other causes of ventricular dysfunction. Myocardial fibrosis is almost always present in patients with non-ischaemic cardiomyopathies. However, the extent, location, and pattern of myocardial fibrosis vary greatly with the type of cardiomyopathy. Whereas most cardiomyopathic processes involve the LV predominantly, some, notably arrhythmogenic right ventricular dysplasia/cardiomyopathy (ARVD/C), predominantly affect the RV.^{85,201,202} In either ventricle, there appears to be a predisposition for myocardial scars that cause VT to involve the perivalvular regions.^{22,61,203} In addition to idiopathic cardiomyopathy, scar-related VT occurs in cardiomyopathies due to: (i) valvular heart disease, (ii) myocarditis, (iii) sarcoidosis, (iv) hypertrophic cardiomyopathy, (v) ARVD/C, and (vi) Chagas' disease and in repaired congenital heart disease.^{22,27,61,85,201-205}

Contrast-enhanced MRI has emerged as a robust tool for the assessment, localization, and quantification of myocardial fibrosis, revealing it in virtually all types of ischaemic and non-ischaemic cardiomyopathies.^{61,139,146,201-210} The pattern and extent of myocardial fibrosis was found to be a predictor of inducible VT in patients with a non-ischaemic cardiomyopathy.¹³⁹ Studies in animal models suggest a future role for analysis of the pattern and extent of myocardial fibrosis in pre-procedural planning for catheter ablation of scar-related VT.

Evaluation prior to catheter ablation

Patients who are being considered for catheter ablation of VT should undergo a careful cardiovascular evaluation prior to the procedure. In addition to a physical examination, routine laboratory evaluation, and ECG, additional testing is warranted aimed at: (i) identifying obstructive coronary artery disease that may warrant revascularization, (ii) defining the precise aetiology as well as the extent of myocardial disease, and (iii) identifying and quantifying the types and burden of sustained and non-sustained ventricular tachycardia (NSVT). Each of these issues is discussed further below.

There are several reasons for assessing the presence of obstructive coronary artery disease. First, MI is a common cause of myocardial fibrosis. Second, during catheter ablation, it may be desirable for the patient to remain in VT for an extended period of time to allow for activation and entrainment mapping. An understanding of the potential risk for ischaemia is important, particularly if haemodynamic instability develops during the procedure. Third, revascularization improves outcome of some patients with significant coronary artery disease. Recurrent SMVT is rarely, however, due to acute myocardial ischaemia. For patients with scar-related VTs, a coronary angiogram or recent exercise or pharmacological stress evaluation should

be considered, but it is not required if the severity of coronary disease has been recently defined and symptoms and haemodynamic tolerance of VT do not suggest significant ischaemia. For patients with frequent or incessant monomorphic VT proceeding to catheter ablation, gaining control of the arrhythmia may be warranted prior to assessment of coronary artery disease.

Patients should undergo evaluation to determine the precise aetiology as well as the extent of myocardial disease. At a minimum, this evaluation should include an echocardiogram and evaluation for obstructive coronary artery disease as described above. For patients found to have a non-ischaemic cardiomyopathy, further evaluation may be undertaken with a cardiac MRI, cardiac CT scan, and an endomyocardial biopsy. At the present time, there is no consensus on which of these tests is required. This reflects, in large measure, the absence of evidence from clinical trials that these diagnostic modalities improve outcome. It is important to identify and quantify the types and burden of sustained VT and NSVT prior to performing catheter ablation. Many patients with scar-related VT will have multiple distinct morphologies and types of inducible VT. Optimally, a 12-lead ECG of the clinical VTs will be available for review at the time of the EP procedure. This information may be used to focus on the exit region suggested by the VT morphology to limit the extent of detailed mapping, particularly when the clinical VT is haemodynamically unstable.

In patients with ICDs, VT is usually terminated promptly and a 12-lead ECG is often not available. The VT cycle length and ICD electrogram morphology data can be used to help identify presumptive clinical VTs, although it should be recognized that this information has the inherent limitations of a single- or two-lead recording system and can be misleading. Despite the limitations of electrogram assessment, some laboratories compare ICD electrogram morphology and rate during spontaneous and induced VT events particularly when trying to limit ablation to targeting presumptive clinical VT.

Assessment for peripheral vascular disease that may make vascular access difficult is reasonable when suspected. When identified, a transseptal approach to the left heart may be considered. Imaging to assess the presence of LV thrombus is recommended prior to LV mapping. Transthoracic echocardiography is usually adequate. Magnetic resonance imaging can also be used.²¹¹ For operators experienced with its use, ICE performed from the right side of the heart at the beginning of the procedure can also potentially detect an LV thrombus. If atrial fibrillation is present and cardioversion may occur during the ablation procedure, the guidelines for anticoagulation management should be followed.¹⁸⁷

Mapping of scar-related ventricular tachycardias

The mapping technique used to identify potential sites for ablation depends on the mechanism of the VT.²¹² Although reentry is extremely common in patients with ventricular scars, focal mechanisms also occur. Activation mapping and pace mapping are most useful for focal mechanisms,

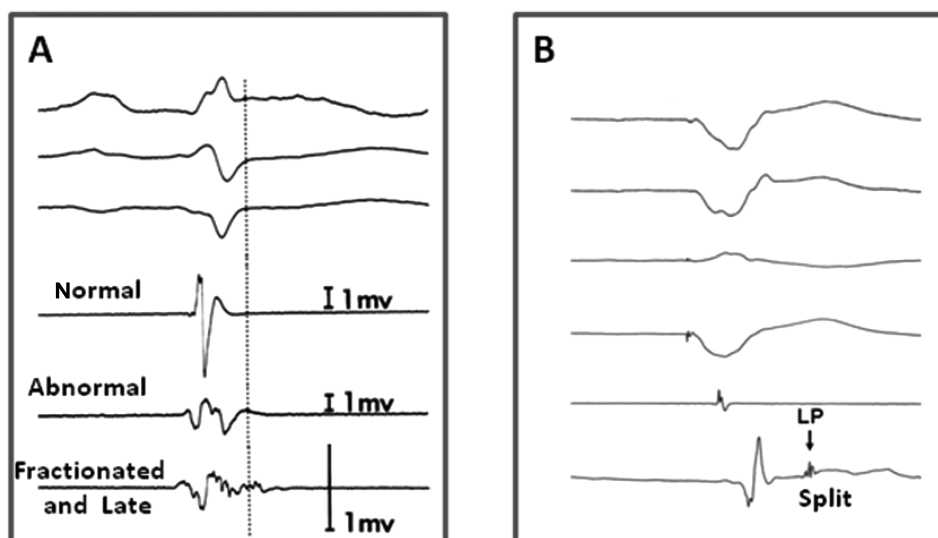


Figure 3 (A) Electrograms types recorded from 2 mm bipolar electrodes with a 5–10 mm interelectrode distance filtered at 30–500 Hz. Normal signals are bi- or triphasic with an amplitude of ≥ 3 mV, duration < 70 ms, and amplitude/duration ratio of < 0.046 mV/ms. All other electrograms are abnormal. Fractionated electrograms are multicomponent signals of long duration (> 133 ms) and low voltage (< 0.5 mV). From Cassidy et al.²²³ (B) An example of an isolated, late, split potential recorded, in this case, during ventricular pacing. Late potentials (LPs) are defined as isolated potentials (LP) occurring > 10 ms after the end of the QRS (sinus rhythm or paced).

whereas substrate mapping (with or without associated pace mapping) and entrainment mapping are used for reentrant mechanisms. Different mapping methods are often complementary, such that a combined approach tailored to the individual patient is often employed. It is important for the electrophysiologist to understand the strengths and weaknesses of the different approaches and mapping systems.

Electrogram recording and interpretation

Mapping relies on the interpretation of electrograms, providing information regarding activation time, evidence of scar, and evidence of abnormal conduction that might be the substrate of reentry. Bipolar, unipolar, and at times simultaneous recording of both unipolar and bipolar electrograms can be helpful.^{212–215}

The characteristics of electrograms are influenced by interelectrode distance, electrode size, the characteristics of the recording system, and filtering. Local activation time in unipolar electrograms is defined as the steepest negative deflection (although several deflections may be present) and coincides with the peak of the first derivative of the signal, or the peak of the high-pass filtered unipolar electrogram.^{212–215} The activation time is independent of wavefront direction. The major limitation of unipolar signals is the presence of a substantial far-field component due to depolarization of tissue remote from the recording site. In scar regions, the far-field component can obscure small local potentials of interest.²¹⁴ Bipolar electrograms represent the difference between the unipolar signals recorded at each pole. Much of the far-field signal is subtracted, such that low-amplitude local potentials are easier to recognize. Either the peak deflection or rapid downslope of the peak deflection of the filtered signal is considered as local activation, based on modelling studies and mapping with fine

(as small as $100 \mu\text{m}$) needle electrodes separated by very short distances ($< 200 \mu\text{m}$ to 1 mm). Similar studies have not been performed for mapping and ablation catheters which have larger electrodes and interelectrode spacing. The peak of the bipolar signal usually coincides with the steepest intrinsic deflection of the two 'local unipolar' recordings. The more rapid the intrinsic deflection on the unipolar signal, the taller the peak of the bipolar signal.

A limitation of bipolar electrograms is the potential for the signal of interest to originate from myocardium below either of the recording electrodes.^{214,216} Since ablation energy is delivered only through the tip electrode, it is imperative that the ablation target be located beneath the distal electrode, rather than the proximal electrode. Simultaneous recording of the unipolar electrograms from each electrode can allow this distinction.²¹⁴ Bipolar signals are direction-dependent and show minimal amplitude if the wavefront is perpendicular to the recording bipolar electrode pair.

Activation times in bipolar signals are difficult to assign or interpret when electrograms have multiple components. Relatively long-duration electrograms with multiple components are referred to as *fractionated*.^{45,217} In areas of scar, each peak of a fractionated electrogram may represent depolarization of a separate myocyte bundle separated by fibrosis from neighbouring bundles, and causing slow conduction (Figure 2).⁴⁵ Electrograms with a long isoelectric period (arbitrarily defined as > 30 – 50 ms) between two spikes are said to be split potentials (Figure 3B). Split potentials may represent block with activation around the site of block or two wavefronts moving in the same or opposite directions at different times. The definition of a normal electrogram will vary depending on the precise recording methods.²¹² From bipolar recordings with 2 mm

electrodes with 5–10 mm interelectrode distance, normal electrograms had amplitudes of >3 mV, width of <70 ms, and amplitude/duration ratios of 0.046 mV/ms (Figure 3A);²¹⁸ fractionated electrograms were defined as multi-component signals of <0.5 mV and duration of >133 ms. With smaller (1 mm) electrodes with narrower (2 mm) interelectrode distances used for intraoperative mapping, normal ventricular electrogram amplitude was >0.6 mV, illustrating the dramatic effect that the recording methods can have on electrogram characteristics.²¹² Studies of substrate mapping have defined normal electrogram amplitude of >1.55 mV using a 4 mm tip electrode with 1 mm interelectrode distance and filtering at 10–400 Hz.⁷³

Activation mapping

Mapping of the electrical activation sequence during VT is a valuable mapping strategy that can be used alone or in conjunction with substrate mapping, entrainment mapping, and/or pace mapping. Activation mapping can be performed by recording and analysing either unipolar or bipolar electrograms. The sequential point-by-point method involves moving an electrode catheter to multiple ventricular locations and recording an electrogram at each site. This approach is greatly facilitated by the use of an EAM system. Although point-by-point mapping is tedious and requires considerable skill with catheter manipulation, it has been widely employed to facilitate catheter ablation of stable VT. Alternatively, activation sequence mapping can be performed using a multielectrode mapping system (see the Techniques section). There is limited experience with basket catheters and multielectrode catheters and these are not routinely used by the members of the task force (see above). Non-contact mapping systems are used in selected patients by some task force members.

For focal VT, the earliest site of activation identifies the tachycardia origin that is targeted for ablation. The QRS provides a convenient fiducial point for mapping. Activation at the origin precedes the QRS onset. In normal tissue, the unipolar signal (with high-pass filter setting <1 Hz) typically demonstrates a QS configuration consistent with the spread of activation away in all directions from the VT origin.

In scar-related reentry, activation mapping is usually limited. Although the term ‘site of origin’ makes sense for focal VT, it is a misnomer in scar-related macroreentry (Figure 2). There is a continuous reentry path with no ‘earliest point’. The QRS onset typically occurs when the impulse reaches an exit along the border zone of the scar and propagates into the surrounding myocardium. Electrograms immediately preceding the QRS are typically recorded from the exit region.^{30,219–221} Exit regions can also be identified by the non-contact mapping system where depolarization propagates away from the scar.^{62,128} At reentry circuit sites that are in a channel proximal to the exit, electrograms are typically earlier, between the QRS complexes (diastolic electrograms). These are often isolated potentials or split potentials.^{30,219,222,223} Sites that are outside the isthmus, in

outer loops or remote from the scar, are typically depolarized during inscription of the QRS. However, sites that are proximal in a reentry circuit, isthmus can be depolarized at the end of the QRS complex.^{30,224} Sites that are outside the reentry circuit are bystanders (Figure 2). The extensive conduction abnormalities in areas of scar can cause bystander regions to depolarize during electrical diastole mimicking the timing of an isthmus site.³⁰ Thus, electrogram timing at an individual site is not a reliable indicator that the site is a desirable ablation target, and entrainment methods are helpful for selecting ablation sites (see below).

For stable VT, complete activation sequences may be defined and used with entrainment mapping to guide ablation. More commonly, limited activation assessment, noting areas of pre-systolic activity and isolated potentials, is performed, and this information is integrated with entrainment mapping data to identify target sites for ablation.

Pace mapping

Pace mapping refers to analysis of the activation sequence, usually assessed from the 12-lead ECG during pacing at a mapping site in the absence of VT. The site where the paced QRS morphology replicates that of the VT is likely to be near the origin for a focal VT or an exit region for scar-related reentry.^{51,225–228}

Either bipolar or unipolar pacing may be used. Bipolar pacing produces a smaller stimulus artefact; there is the possibility of capture at the proximal ring electrode as well as at the tip electrode that may reduce accuracy, particularly if larger interelectrode distances (8–10 mm) and high-current strength (>8 mA) is used.²²⁷ Pacing slightly above threshold is likely to improve accuracy by limiting the size of the virtual electrode and reducing the likelihood of anodal capture at the proximal ring electrode during bipolar pacing when there is good contact at the contact at the tip electrode.²²⁹ However, repetitive threshold determinations are often not practical. Some laboratories initially pace with 10 mA, 2 ms stimuli and occasionally decrease stimulus strength if a broad area of capture is suspected, or increase stimulus strength (e.g. up to 20 mA) if required to capture tissue in a scar region.^{53,230} Whether the use of body surface mapping or automated algorithms to quantitate comparison of QRS morphologies during VT and pace mapping improves the clinical utility of pace mapping is not yet known.^{231,232}

For focal VTs, pace mapping may be used to suggest the location of the origin, although activation sequence mapping is probably more accurate.^{10,227,233,234} The optimal site should exactly match the tachycardia QRS, including individual notches as well as major deflections. Pace mapping can be particularly useful if the targeted arrhythmia is difficult to induce.

For scar-related VTs, pace mapping at the exit region will match the VT QRS. However, the potential for large reentry circuits and abnormal conduction creates several limitations and caveats. Pacing in normal areas outside the exit can produce a similar QRS morphology to VT. Thus,

pace mapping is often combined with a voltage map during substrate mapping to define the potential exit.^{73,235} Although pacing in the reentry circuit near the exit may produce a QRS similar to that of VT, pacing at sites more proximal in the reentry circuit isthmus during sinus rhythm may produce a markedly different QRS and ECG pattern, as the stimulated wavefront propagates away from the site via paths that are blocked during VT.^{225,226,228,235} Thus, when pacing in regions of scar, a QRS that does not match the VT does not reliably indicate that the site is outside of the reentry circuit.

Sites where the stimulus to QRS interval exceeds 40 ms are consistent with pacing in regions of slow conduction.^{53,228,235} In some reentry circuit isthmuses, pacing produces a long S-QRS and a QRS morphology that matches that of VT.^{51,53,235}

Entrainment mapping

Entrainment mapping is useful for identifying reentry circuit sites and recognizing bystander sites in stable VT. Entrainment is performed by pacing faster than VT.^{30,219,222,223,225,236-243} During reentrant VT, a stable QRS morphology with resumption of tachycardia on termination of pacing indicates that each stimulated wavefront has reset the reentry circuit, entraining the tachycardia. Entrainment can be confirmed by the presence of constant fusion, progressive fusion, or evidence of conduction block terminating tachycardia.²⁴¹

Entrainment mapping is critically dependent on the assumption that pacing is not altering conduction through the circuit. Pacing should be performed at a cycle length that is only modestly faster (10–30 ms shorter) than the VT cycle length to reduce the chance of terminating or altering the VT. Pacing at an output that is just above threshold to avoid capture of remote myocardium is desirable, but repeated threshold determination is not always practical. Pacing at 10 mA at 2 ms stimulus strength is reasonable and stimulus strength can be reduced if desired. At some sites in scar, greater stimulus strength is required to capture and identify reentry circuit sites.²³⁰ Although some investigators use unipolar pacing to limit the potential for anodal capture, bipolar pacing is used effectively by many laboratories.^{30,219,236-244}

At sites in the reentry circuit, the post-pacing interval at the site of stimulation approximates the revolution time through the circuit, which is the tachycardia cycle length. The post-pacing interval increases with increasing conduction time between the pacing site and circuit. There are several potential sources of error. The post-pacing interval is measured to the local potential. In areas of scar with fractionated and split potentials, distinguishing the local potential from far-field signals due to depolarization of tissue remote from the pacing site can be difficult.²¹⁶ Electrical noise and stimulus artefact can obscure electrograms during entrainment.^{245,246} If pacing slows conduction in the circuit, the post-pacing interval prolongs.

The QRS morphology during entrainment indicates whether the pacing site is likely to be in an isthmus. At sites

that are remote from the VT circuit, pacing changes the QRS morphology producing either QRS fusion or a paced QRS that resembles that which occurs in the absence of VT. At reentry circuit isthmus sites, pacing entrains VT without changing the ventricular activation remote from the circuit because the paced wavefronts use the VT exit to activate the ventricle. The QRS complex during entrainment is the same as that during VT, a finding that has been designated concealed entrainment, entrainment with concealed fusion, or exact entrainment. At these isthmus sites, the S-QRS interval, which indicates the conduction time from the pacing site to the exit, is the same as the electrogram to QRS interval. In contrast, at bystander sites that are adjacent to the reentry circuit isthmus, entrainment may occur without QRS fusion, but the post-pacing interval (PPI) will exceed the VT cycle length and the S-QRS will exceed the electrogram to QRS interval.^{30,247} Sites with long S-QRS (>70% of the VT cycle length) with concealed fusion and a PPI indicating that the site is in the circuit often seem to be proximal to the isthmus region (inner loops), with a lower likelihood of VT termination by RF ablation.

Sites that are in an outer loop of the reentry circuit along the border of the scar can be recognized by a post-pacing interval that approximates the VT cycle length, but with QRS fusion during entrainment. Because surface ECG fusion can sometimes be difficult to recognize, careful attention needs to be paid to analysing all 12-ECG leads during pacing and comparing the QRS morphology with pacing to that of the VT. QRS fusion is often not detected when <22% of the QRS duration is due to the antidromic wavefront.²⁴⁸ Therefore, some outer loop sites are misidentified as exit sites or inner loop sites.

In patients with haemodynamically tolerated VT, ablation at isthmus sites identified by entrainment mapping often terminates VT.^{219,222,223,243,249} Ablation at isthmus sites that also have an isolated mid-diastolic potentials most consistently terminates VT with limited RF energy application, with a low risk of recurrent VT during follow-up.^{219,223,238} In patients with unstable VT, limited entrainment mapping has been combined with substrate mapping to target regions of the scar for ablation.^{28,59}

Substrate mapping

Substrate mapping is the characterization of areas likely to support reentry based on anatomy and electrophysiological characteristics that can be determined during stable sinus or paced rhythm. This approach can facilitate ablation of multiple VTs, pleomorphic VTs, and VTs that are unmappable due to haemodynamic instability or that are not reliably inducible.^{50,53,55,59,73,95,99,101,250-255} Even for haemodynamically stable VTs, substrate mapping is commonly used to limit activation sequence mapping or entrainment mapping to a region of interest. In these cases, the voltage map that identifies scar regions may be obtained during VT.¹⁰⁴

Substrate mapping generally begins with identification of the region of ventricular scar, based on electrogram characteristics (usually voltage) in an electroanatomic map of

the ventricle of interest. Markers for reentry circuit exits, channels (isthmuses), and regions of slow conduction, identified based on pace mapping and electrogram properties, are then targeted for ablation. Given the less precise localization of the reentry circuit, a more extensive ablation approach involving the delivery of energy over a relatively large area within the scar is commonly employed.

Identification of scar. Scar tissue can be identified based on bipolar electrogram amplitude. Using a 4 mm tip electrode and 1 mm ring interelectrode spacing with a 2 mm ring (1 mm interelectrode distance) filtered at 10–400 Hz, 95% of normal LV endocardial electrograms have a peak-to-peak amplitude >1.53–1.55 mV.⁷³ A good correlation has also been found between low-voltage areas and scar in animal models.²⁵⁶ Areas of extremely low voltage (<0.5 mV or even less) have been designated as ‘dense scar’, but it is important to recognize that these regions can still contain viable myocytes and reentry circuit isthmuses.⁵³ The area of intermediate low voltage with signal amplitude between 0.5 and 1.5 mV designated as being within the border zone was initially targeted as being an area of particular interest given the success of the subendocardial resection for surgically eliminating VT.⁷³

Exits and channels. The area of scar is often large, averaging 21 cm in circumference in one study of post-infarction patients.⁵⁹ In order to limit the area of ablation within the scar, a region of the scar is targeted for ablation based on pace mapping or additional electrogram characteristics. Radiofrequency lesions are generally confined within the low-voltage region to reduce the risk of damage to functioning myocardium.

Exits can be identified based on pace mapping along the border of the scar. Radiofrequency lesions can then be placed in the infarct border zone (where bipolar electrogram amplitude is typically between 0.5 and 1.0 mV) roughly parallel to the infarct border; additional lines of ablation lesions perpendicular to the border, extending through the exit region into the dense scar region, may also be added.^{73,101,252,253} Whether identifying a site with a ‘perfect’ pace-map QRS match with VT achieves better results than ablation through a region identified as having a ‘good’ pace-map match is not known.

Several markers of potential isthmuses have been described.^{50,51,55,95,99,250,250a} Sites where pacing produces a long S-QRS but matches the VT QRS morphology are seen at some reentry circuit isthmus sites and can be targeted for ablation.⁵¹ Areas of late potentials and split potentials with an isolated diastolic component are observed at some reentry circuit isthmus sites during sinus or paced rhythm and have been targeted for ablation.^{50,95,99,263} Potential channels within the low-voltage scar have been identified by manipulating the upper boundary of the colour scale to expose relatively higher voltage channels bordered on either side by low-voltage

regions of dense scar. Targeting these channels has also shown promising results in single-centre studies.^{55,250}

Areas of electrically unexcitable scar can be defined and marked based on a high pacing threshold (>10 mA at 2 ms during unipolar pacing).⁵³ In some patients, these unexcitable regions define channels that can be targeted for ablation.

Substrate-guided ablation is a reasonable strategy for VT ablation when mapping cannot be performed during a stable VT. It can also be used to help direct ablation of scar-related stable VTs. Whether it should be considered in patients with inducible VT following ablation of a clinical VT is not known. The different criteria for identifying exits and placing RF lesions have not been directly compared.

Endpoints for ablation

The endpoint of ablation in patients with scar-related SMVT, and the acute success of the procedure, is assessed most commonly by programmed ventricular stimulation, typically employing up to three extrastimuli at one or more RV (and occasionally LV) sites. This endpoint is subject to the limitations of programmed stimulation in reproducing spontaneous VT at the onset of the study. The utility of various endpoints has been judged by spontaneous recurrence rates during long-term follow-up. These data are limited by several factors, including (i) the intrinsic reproducibility of VT induction, (ii) short-term alterations in autonomic tone, loading conditions and fibre stretch, and acute ischaemia, (iii) alterations in post-ablation antiarrhythmic drug therapy, and (iv) long-term evolution and progression of underlying myocardial and coronary disease. In addition, temporal evolution of ablation lesions may alter the immediate post-ablation substrate, producing either lesion expansion (mediated in part by secondary myocyte loss due to disrupted microcirculation) or regression (resolution of oedema and healing), thus altering susceptibility to VT. Techniques and strategies have evolved over the past 2 decades, resulting in a greater diversity of patients undergoing ablation, including those with multiple QRS morphologies, unstable VT, and patients in whom a clinical (or any) VT cannot be induced at baseline. The correlation of outcome to endpoints derived from early reports in highly selected subgroups may not be applicable to contemporary patients undergoing VT ablation.

Overall, three general endpoints have been evaluated: (i) non-inducibility of clinical VT, (ii) modification of induced VT cycle length (elimination of all VTs with cycle lengths equal to or longer than spontaneously documented or targeted VT), and (iii) non-inducibility of any VT (excluding ventricular flutter and fibrillation). Although a change in the ‘intensity’ of stimulation required to induce VT (greater number of extrastimuli and alternative stimulation sites) has occasionally been used to indicate a beneficial response to ablation, there is little evidence to support this claim. Direct comparisons of different endpoints are limited, and the majority of data derive from single-centre studies.

Non-inducibility of clinical ventricular tachycardia

Many studies have described outcomes in terms of inducibility of *clinical VT*, a term that has been used to refer to VT that has occurred spontaneously (Table 1). There are many problems and assumptions with this designation. The minimum number of ECG leads required to discern differences between different VT origins or circuits is not clear. Furthermore, differences in ECG lead placement, patient position, and antiarrhythmic drugs may influence the similarity between two episodes of VT that arise from the same circuit. Some studies have used a frontal plane axis within 45° and the same dominant deflection in V1 to designate an induced VT as similar to a spontaneously occurring VT.²⁵⁷ The VT cycle length alone is influenced by antiarrhythmic drugs and can be similar for different VTs or may be different for VTs originating from the same region, and is therefore unreliable as a sole indicator of clinical VT. The task force members recommend that the term *clinical VT* be reserved for induced VTs that are known to have the same 12-lead ECG QRS morphology and approximate cycle length as a spontaneous VT. Other VTs should be designated as *presumptive clinical* or as *previously undocumented VT morphology* (Table 1).

When clinical VT(s) can be documented prior to the procedure and induced at the onset of ablation, non-inducibility of clinical VT immediately post-procedure is associated with a lower risk of VT recurrence (up to 37%), compared with persistent inducibility of clinical VT (up to 80%).^{59,178,254,257,258} In patients with a single stable spontaneous morphology, the persistent induction of 'non-clinical' VT was reported to have little influence on subsequent spontaneous recurrence rates.²⁵⁹

Modification of inducible ventricular tachycardia

With evolving trends in the management of VT, including widespread use of ICDs, the clinical VT is most often unknown, or at best inferred from a limited number of telemetry leads or ICD logs of stored rates and electrogram morphologies. A large majority of patients have multiple monomorphic VTs induced (mean of ~3 per patient), including previously undocumented VT morphologies. As a result, a surrogate endpoint employed in many laboratories has been the elimination of all VTs with cycle lengths equal to or longer than those documented spontaneously. This approach is reported to be associated with a lower risk of recurrent VT in some,^{59,260} but not all, laboratories.^{254,257,261} While persistently inducible 'non-clinical' VTs are often faster than those targeted for ablation, the occasional spontaneous occurrence of these rapid VTs during follow-up is well documented.^{119,186,254,257,261,262}

Non-inducibility of any ventricular tachycardia

Single-centre experience reflecting more diverse populations demonstrate that inability to induce any VT is associated with the lower recurrence rates in most,^{257,261,262} but not all,¹¹⁹ studies. The prognostic significance of eliminating all inducible VT is supported by the results of two recent multicentre trials. The Thermocool VT Ablation Trial evaluated endpoints in 231 patients with both stable and unsta-

ble post-infarction VT undergoing ablation by a combination of mapping and substrate-based strategies,¹⁰⁵ 49% of patients had no inducible VT post-procedure, whereas an additional 33% had inducible VT that was faster than that induced at baseline stimulation. Induction of any VT post-ablation was associated with a significantly greater risk of VT recurrence (nearly 2-fold), while persistent induction of more rapid VT only, as well as the cycle length of the post-ablation-induced VT, did not predict recurrence. The Euro-VT-Study evaluated outcome of ablation in 63 patients with both stable and unstable post-infarction VT.¹⁰⁶ The endpoint of non-inducibility or induction of VT more rapid than clinically documented VT was achieved in 81% of patients and did not predict the risk of VT recurrence.

Although the majority of outcome studies focused on the correlation of inducibility to even a single recurrence of VT during follow-up, this criterion may be overly stringent. Substantial reduction in VT episode frequency occurs in a majority of patients during follow-up, even if occasional recurrences of VT persist. In a multicentre study of 145 patients with either ischaemic or non-ischaemic cardiomyopathy who had at least one stable or mappable VT, 89% of patients had at least one clinical VT identified.¹⁶⁰ During follow-up, clinical success was defined as >75% reduction in VT episodes. Persistent induction of clinical VT post-ablation was associated with a greater than four-fold increased risk of failure; induction of any VT post-ablation was not predictive of this outcome. A single-centre series also suggests that ablation of clinical VT (but not necessarily all VT) is associated with a lower incidence of electrical storm and cardiac death, despite a high likelihood of sporadic VT recurrence.²⁶²

Finally, newer substrate approaches and patient populations may require additional and/or alternative endpoint criteria. When isolated, late diastolic potentials in sinus rhythm are targeted for ablation; elimination of these potentials post-ablation (or a subset with the greatest delays) has been advocated as useful endpoint.^{50,95} In patients with recurrent episodes of primarily PMVT or VF, ablation of a limited number of uniform premature ventricular complex (PVC) morphologies that were documented to trigger spontaneous episodes has been associated with a substantial reduction in recurrences during long-term follow-up.^{264,265} Whether these endpoints are sufficient as predictors of freedom from long-term recurrences compared with the outcome of programmed stimulation requires further investigation, but they may be particularly useful when VT cannot be induced at the onset of the ablation session.

The consensus of the task force members is as follows. When clinical or presumed clinical VTs have been adequately documented previously and can be induced at the outset of the procedure, the minimum endpoint of ablation should be to eliminate the induction of that VT during post-procedure programmed stimulation. The stimulation protocol should include up to three extrastimuli delivered from at least two ventricular sites (one of which may be

LV), with shortest coupling intervals of 180–200 ms or to refractoriness. If the initial stimulation protocol required additional LV pacing sites or catecholamine infusion to induce VT, then that protocol should be repeated following ablation. In patients who present with incessant VT, restoration of stable sinus rhythm represents a reasonable clinical endpoint, irrespective of the outcome of subsequent programmed stimulation. The task force members did not reach consensus on whether complete elimination of induced VT should be employed as the primary and routine procedural endpoint, and acknowledges the need for additional data and further research to clarify optimal endpoints for VT ablation in various clinical settings. Finally, the group recognizes that some patients undergoing VT ablation have significant haemodynamic compromise and substantial ischaemic burden often aggravated by prolonged periods of tachycardia. Post-procedure stimulation to assess VT inducibility should be avoided if in the judgement of the physician, it places the patient at risk of cardiopulmonary deterioration.

It is strongly recommended that reports of ablation procedures include specific information regarding the extent of post-procedure programmed stimulation, endpoints used, the cycle lengths, and morphologies of post-procedure-induced VTs, and their relationship to previously documented spontaneous VT when known. If post-procedure programmed stimulation is omitted or truncated, the reason should be specified. These data should also be explicitly elaborated in case series and multicentre trials of the outcome of VT ablation submitted for publication.

Ablation strategies

Endocardial ablation

Selection of the strategies for endocardial ablation should consider the type and severity of underlying heart disease, the underlying arrhythmia substrate, characteristics of the VT, the mapping and ablation technologies available and the optimal vascular access routes (retrograde aortic or transseptal approach to the LV). A variety of strategies are reasonable. In general, it is desirable to first induce VT, to confirm the diagnosis, to evaluate the possibility of bundle branch reentry, to establish inducibility for interpretation as an endpoint, and to record the 12-lead ECG morphology of VT in the electrophysiology laboratory.

When there is a clear clinical VT that is haemodynamically tolerated, and particularly when the VT is incessant, a combination of activation sequence mapping and entrainment mapping to identify a critical isthmus for ablation are reasonable.^{54,180,223} Once VT is terminated by ablation, additional lesions may be placed creating ablation lines that meet valve annuli or dense unexcitable scar that may form borders of the reentry path.

More commonly multiple VTs are present, some of which may be haemodynamically tolerated for a variable period, and others that are not tolerated. Many centres then start with substrate mapping during stable sinus rhythm.

Brief episodes of VT can be induced to assess the potential location of the reentry circuit, with prompt termination of VT if required to help select the ablation region.^{59,99} Alternatively, ablation can be performed guided by substrate characteristics.^{73,95,99,101,250} These different approaches have not been directly compared.

The extent and pattern of RF lesions guided by these approaches also varies. Many centres place a line of RF lesions parallel to and within the low-voltage border of the scar through presumptive exit regions.^{28,73} Ablation within the low-voltage area at sites with features of channels is another strategy. These have not been compared. It is generally recognized that channels are often located adjacent and frequently parallel to a valve annulus, such that ablation in areas that are near a valve annulus is often extended through the scar to the valve annulus, in the hope of transecting the isthmus.^{28,55,57,73}

The optimal RF ablation endpoints for assessing lesion creation are not known. Termination of VT during RF application with prevention of reinitiation, diminution of electrogram amplitude, increase in unipolar pacing threshold to >10 mA, and arbitrary duration of ablation with impedance fall and temperature indications of adequate heating have all been used and are considered reasonable by the task force.^{53,59,73} Endpoints for the procedure are discussed above.

Epicardial mapping and ablation

Ventricular tachycardia originating from the subepicardium is an important cause of failure of endocardial ablation approaches.^{56,266–268} A percutaneous epicardial mapping approach allows many of these VTs to be ablated in the electrophysiology laboratory.^{29,267} Catheter ablation from the epicardium is often required for ablation of VTs due to non-ischaemic cardiomyopathy and is occasionally useful for VTs in a variety of other diseases, as well as some idiopathic VTs. In a recent survey of three tertiary centres performing VT ablation, 17% of procedures involved epicardial mapping, not all resulted in epicardial ablation, however.²⁶⁹ Data are from a few experienced centres and there are significant technical challenges and risks.

Technical considerations. The procedure may be performed using conscious sedation and local anaesthesia, but some operators feel that deep sedation with the support of an anaesthesiologist or general anaesthesia may allow better control of respiratory motion, which might reduce the chance of unintentional RV puncture. From the subxiphoid approach, a 17 or 19 G Tuohy needle is gently advanced, under fluoroscopic observation to the edge of the cardiac profile.^{29,267,270} Directing the needle towards the left shoulder with an angle of $\sim 45^\circ$ relative to the skin surface is generally used to reach the inferior wall. A shallow angle is used if an anterior approach is desired (Figure 4).

Entry into the pericardial space is indicated by negative pressure (concave meniscus at the proximal end of the needle) or by injection of a small amount of contrast that

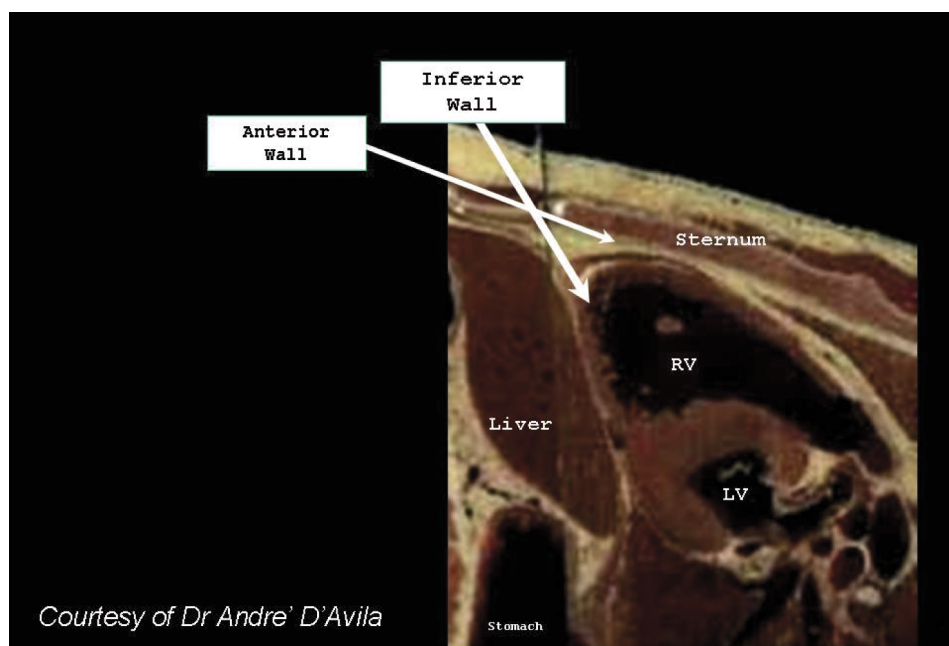


Figure 4 A sagittal anatomical cross section showing approaches for percutaneous pericardial entry. RV, right ventricle; LV, left ventricle.

distributes into the pericardial space. A soft-tipped guide-wire is then inserted through the needle into the space. Confirmation that the wire is intrapericardial and has not been inadvertently inserted into a cardiac chamber is obtained by observing the course of the wire in multiple fluoroscopic projections confirming that it crosses multiple cardiac chambers, hugging the cardiac silhouette. An introducer sheath is then advanced into the pericardial space, allowing free access to any mapping and ablation catheter.

Attempted epicardial access fails in ~10% of patients.²⁶⁹ Pericardial adhesions from prior pericarditis or cardiac surgery is usually the cause, although limited access may be possible in some of these patients.^{269,271} Surgical creation of a pericardial window and manual dissection and lysis of the lesions to allow catheter mapping and ablation in the electrophysiology laboratory have been shown to be feasible in small series.^{251,272}

The approach to mapping is essentially the same as for endocardial ablation, including activation mapping, entrainment mapping, substrate mapping, and pace mapping.^{29,86,87,251,272,273} At some sites, pace mapping and entrainment mapping may be limited by a high stimulation threshold due to epicardial fat.²⁷⁴ Epicardial fat can cause low-amplitude electrograms, falsely suggesting scar in voltage maps.^{85,251} Fractionated and split potentials may be a more reliable indication of scar.

Reported series have generally used RF ablation. Due to the lack of convective cooling of the ablation electrode by the circulating blood, high electrode temperatures may be encountered at low-power settings (10 W or less), limiting lesion creation.¹⁶⁵ Epicardial fat can limit lesion creation.¹⁶⁵ Open or closed loop irrigation allows the delivery of energy at power settings (25–50 W) capable of creating deep le-

sions (up to 5 mm) that can be effective even in the presence of adipose tissue.²⁷⁴

Optimal parameters for RF power titration and irrigation are not completely defined. With external irrigation flow of 0–2 mL/min may be used during mapping, increasing to 10–30 mL/min during ablation, as required to maintain electrode temperature <50°C. Careful power titration starting at 20–30 W to a maximum of 50 W is commonly employed. Monitoring for an impedance fall is commonly used to assess likely adequate power delivery.¹⁶⁵ With open irrigation, fluid must be periodically drained from the pericardium. This can be accomplished by intermittently removing the ablation catheter to allow aspiration from the pericardial sheath, placing a second pericardial catheter for drainage purposes, or using a single sheath that is larger than the ablation catheter, allowing aspiration of fluid around the catheter from the side port.

The absence of circulating blood in the pericardial space theoretically should facilitate cryoablation,^{166,270} but there is limited human experience. Cryoablation did not produce significantly larger lesions than irrigated RF in an animal model.²⁷⁰

Complications and risks. Some degree of pericardial bleeding is recognized in ~30% of cases.²⁷⁰ Unintentional RV puncture and pericardial bleeding is a well-recognized potential complication and a reason to avoid performance of pericardial puncture in the presence of systemic anticoagulation. In some cases, puncture of the RV is not followed by significant pericardial bleeding. Mild or modest bleeding usually resolves and can be carefully monitored with repeated aspiration of the pericardial space, as the procedure continues.¹³⁵ Severe bleeding requiring surgical interven-

tion can potentially occur.^{29,270} There is concern that abrasion or laceration can occur if a stiff vascular sheath is left in the pericardium without a catheter protruding from the lumen. Precautions must be in place for managing severe bleeding, including availability of appropriate surgical expertise. When bleeding stops, or when pericardial access is achieved without pericardial bleeding, anticoagulation has been administered to allow endocardial mapping without adverse consequences. Puncture of a subdiaphragmatic vessel causing intraabdominal bleeding has occurred and can potentially require surgery.^{270,275} Hepatic laceration and bleeding is also a potential risk.

Radiofrequency injury to coronary arteries can cause acute thrombosis or may produce damage to the arterial wall that is evident on histological examination in animal models, the significance of which is unknown.^{274,275} Severe coronary artery spasm has also occurred during epicardial mapping.²⁶⁹ Prior to ablation, direct visualization of the relation between the ablation site and adjacent coronary arteries must be obtained, usually by coronary angiography performed with the ablation catheter on the target site. An absolute safe distance between the ablation site and epicardial artery has not been defined, and likely varies depending on the RF energy applied, coronary artery diameter and flow, and the presence of overlying fat.^{274,276} Based on available data and experience, a distance of >5 mm between the ablation catheter and an epicardial artery is commonly accepted.^{274,275,277,278}

Cryoablation appears to have less risk of coronary injury in animal models, but can still create occlusion and intimal damage, when in close proximity, particularly to small vessels.^{167,279} More data are needed regarding long-term safety and potential effects of ablation in proximity to coronary arteries.

The left phrenic nerve is potentially susceptible to injury along its course adjacent to the lateral LV wall.^{280,281} Proximity to the nerve can be detected by pacing (typically at 10 Ma or greater stimulus strength) to detect diaphragmatic stimulation, allowing its course to be marked on a three-dimensional map.⁸⁶ Detection by pacing is prevented by the use of paralytic agents during general anaesthesia. Catheter ablation should be avoided at sites adjacent to the phrenic nerve. Alternatively moving the nerve away from the myocardium by injection of air into the pericardium or placement of a balloon catheter between the ablation site and nerve has been reported.^{282,283} Air in the pericardial space can increase the defibrillation threshold, requiring emergent evacuation if defibrillation is required.²⁸⁴

Symptoms of pericarditis are common after the procedure, occurring in ~30% of cases.²⁷⁵ Symptoms usually resolve within a few days with anti-inflammatory medications. Pericardial instillation of aglucocorticoid has been shown to reduce inflammation in a porcine model, and this practice has been adopted by many centres.²⁸⁵

Indications and outcomes. Patients with scar-related or idiopathic VT may benefit from an epicardial approach if endocardial ablation fails. Patients reported have generally been referred to specialized centres, often after failing endocardial ablation; thus, the incidence of epicardial VTs is unknown. In the majority of reported cases, epicardial ablation has been performed as a second, separate intervention following failure of an attempted endocardial approach.^{86,251,262,266} Endocardial mapping in these cases may show a focal endocardial exit that is actually breakthrough from an epicardial VT origin.^{74,86} Electrocardiographic criteria that suggest an epicardial origin may help guide the procedure, although exceptions occur.²⁸⁶⁻²⁸⁸ For VT with RBBB-like configuration, a slurred upstroke creating the appearance of a pseudo-delta wave favours an epicardial origin.²⁸⁸ In LV cardiomyopathies, a Q-wave in leads felt to reflect the VT exit region may favour an epicardial exit.²⁸⁷

Combined endocardial and epicardial mapping procedures are feasible and would be expected to reduce the number of procedures required for patients with suspected epicardial VTs.^{87,251,289,290} Most investigators feel that epicardial access should be achieved before systemic anticoagulation. If pericardial entry is achieved with no bleeding or modest pericardial bleeding that stops, anticoagulation can be administered to allow endocardial LV mapping, followed by continued monitoring for recurrent pericardial bleeding. Experience is limited, however, and caution is warranted. Epicardial mapping and ablation may be useful as a first procedure when endocardial mapping is not an option due to intraventricular thrombi.^{288,291}

In patients with coronary artery disease, epicardial ablation appears to be more frequently required for inferior wall infarct VTs than for those from anterior wall infarcts.^{135,166,251,266,290,292} In one series of 14 consecutive patients with prior inferior wall infarction, a successful epicardial ablation site was found for 7 of 30 VTs (23%).²⁷¹ Epicardial VTs have been observed in ~10% of post-infarction VTs in another series.²⁹⁰ The risk of recurrent VT after acutely successful epicardial ablation appears to be low, although second procedures are occasionally required.²⁶⁶ No serious complications were reported in these series.

Epicardial mapping and ablation is needed more often in patients with SMVT associated with dilated, non-ischaemic cardiomyopathy than in patients with prior infarction, although only a small number of patients are reported.^{86,135,166,251,288,292} Voltage maps consistently demonstrate areas of scarring that are often more extensive on the epicardium than on the endocardium.^{86,87,251} Epicardial reentry circuits are frequent in Chagas' disease.²⁹

Small series and anecdotal reports have also reported successful ablation of epicardial VTs following a failed endocardial ablation in patients with idiopathic OT-VTs, VTs originating from the mitral annulus, the crux of the heart, idiopathic ventricular aneurysms, ARVD, and non-

compaction of the LV.^{86,135,166,251,288,292} Idiopathic OT-VTs that are epicardial in location may originate close to the anterior interventricular vein, great cardiac vein, and middle cardiac vein; and successful ablation from within these structures has been reported.^{164,293,294}

Surgical ablation of ventricular tachycardia

With the availability of implantable defibrillators and catheter ablation, arrhythmia surgery for VT has become uncommon. Surgery is a reasonable alternative, however, for treatment of recurrent VT, in patients with prior MI with LV aneurysms, particularly if significant coronary disease requiring revascularization is present.²⁹⁵⁻²⁹⁷ Careful patient selection and a centre with experience are important. Surgery is also an option for selected patients with VT late after repair of Tetralogy of Fallot and in some selected patients with non-ischaemic heart disease and difficult to control arrhythmia.²⁹⁸⁻³⁰⁰

Intracoronary ethanol ablation

The feasibility of intracoronary injection of ethanol for VT ablation was demonstrated in the early 1990s,^{154,301-303} but endocardial or epicardial catheter ablation is currently preferred. Transcoronary ethanol ablation may be considered when both endocardial and epicardial ablation fail to control severely symptomatic, drug refractory VT.^{304,305} In a large VT referral centre where this treatment was available, it was used in only 1.4% of VT ablation procedures.³⁰⁴

Transcoronary ethanol ablation should only be performed in centres with experience in both VT ablation and ethanol septal reduction for hypertrophic obstructive cardiomyopathy. A cardiologist experienced in the technique of alcohol ablation should perform the procedure with an electrophysiologist. Coronary anatomy must be carefully correlated with endocardial and epicardial mapping studies to select the target branch likely to supply blood to the reentry circuit.^{304,306} If VT is haemodynamically tolerated, iced saline can be injected in an attempt to terminate VT, providing evidence that the vessel supplies the VT circuit. If a coronary target can be identified, a technique similar to that described for alcohol septal ablation in obstructive cardiomyopathy can be used.^{304,307-309} Injection of contrast after proximal balloon occlusion of the target branch allows delineation of the region receiving blood supply from the branch. The presence of collaterals should be carefully analysed as they may allow spread of ethanol to unintended territories. With the balloon inflated to occlude the branch proximally and prevent damage from backflow, absolute alcohol (96%) is slowly injected (typically 1–2 mL over 2–5 min with balloon inflation during 10 min) and can be repeated if needed.³⁰⁴ Control angiography is performed to confirm occlusion of the distal vessel.

Alcohol ablation has several limitations. There is significant potential for extensive myocardial damage and complications including heart block, worsening heart failure, ventricular rupture, and death.^{304,310} A satisfactory target vessel cannot always be identified or cannulated.

VI. Ablation outcomes and considerations in specific diseases

Prior myocardial infarction

Ventricular tachycardia occurs in 1–2% of patients late after MI, often after an interval of several years. Early reperfusion of infarct-related arteries results in less aneurysm formation, smaller scars, and less extensive electrophysiological abnormalities,³¹¹ although a significant risk of late VT (often with rapid cycle lengths) persists.³¹² In addition, the number of at-risk patients with chronic ischaemic cardiomyopathy due to multiple infarctions and late remodelling has increased due to improvements in long-term medical care.³¹³ The mechanism of VT is usually macroreentry;^{32,54,71} focal non-reentrant mechanisms are responsible for fewer than 5–10% of VTs.⁵⁸

Programmed stimulation induces VT in over 90% of patients with a history of VT, although the rate and QRS morphology of induced VT may differ from that observed during spontaneous tachycardia.^{32,54,71} The link between spontaneous and inducible VT remains incompletely understood. However, the induction of VT signifies the presence of a fixed anatomic substrate associated with an increased likelihood of future spontaneous events.^{32,54,71} Episodes of sustained VT are a marker for increased mortality and reduce quality of life in patients who have implanted defibrillators.⁷⁶⁻⁸⁰ Antiarrhythmic medications can reduce the frequency of ICD therapies, but have disappointing efficacy and side effects.⁸¹⁻⁸³ Ablation has an important role for controlling VT in this population.

Post-infarction VT poses several challenges for ablation. The majority of VTs are haemodynamically unstable and multiple VTs (an average of 3 per patient) due to separate reentry circuits or shared areas of slow conduction with variable exits from the scar are common.^{32,57,71,105,314} Reentry circuit channels may be narrow and easily transected with ablation, but can also be relatively broad (>2–3 cm).⁵⁴ For these reasons, activation and entrainment mapping in post-infarction VT have been increasingly supplemented and/or replaced by substrate mapping approaches.

Outcomes

Patient series reported from single centres vary in disease severity, stability of VT for mapping, methods for mapping and ablation, and ablation endpoints. Of 802 patients from 19 centres reported since 2000, at least one VT was ablated in 72–96% of patients and all inducible VTs were ablated in 38–72% of patients.^{53,54,59,62,95,98,99,101,119,129,178,219,250,251,257,258,261,315,316} Procedure-related mortality was 0.5%. For the 13 studies with mean follow-up of 12 months or more, 50–88% of patients were free of any VT, with 30–100% continuing on previously ineffective antiarrhythmic medications. Mortality during follow-up ranged from 0 to 32%.

The Multicentre Thermocool Ventricular Tachycardia Ablation Trial enrolled 231 patients with recurrent VT (median of 11 episodes in the previous 6 months) for ablation with open irrigation RF guided by an EAM using substrate and/or entrainment mapping approaches.¹⁰⁵ Median LVEF

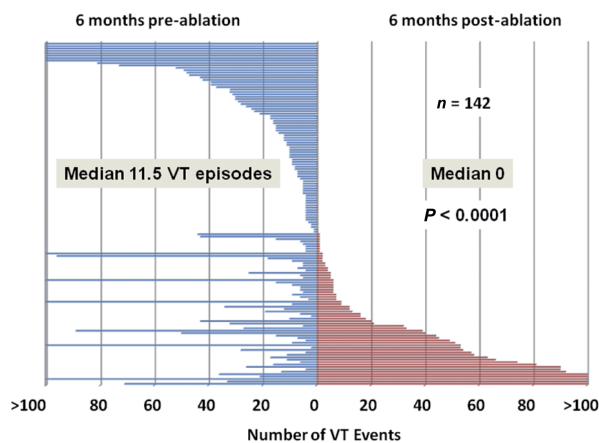


Figure 5 Plot showing the frequency of VT during the 6 months before (blue lines) and after (red lines) ablation for 142 patients with ICDs before and after ablation who survived 6 months (excluding patients with incessant VT). Each line represents an individual patient, arranged by recurrences from greatest (bottom) to fewest (top). The frequency of VT episodes was reduced by $\geq 75\%$ in 67% of patients. Upper boundaries are artificially truncated as indicated at 100 episodes. Reproduced with permission from Stevenson et al.¹⁰⁵

was 0.25, age was 68 years, 62% had a history of heart failure, 70% had failed amiodarone, and 94% had an ICD. Patients had a median of three inducible VTs and unmappable VT was present in 69% of patients. Ablation abolished at least one VT in 81% of patients and all VTs in 49% of patients. During the following 6 months, 51% had recurrent VT. Although recurrences were common, the frequency of VT was markedly reduced in a substantial number of patients (Figure 5). In 142 patients who had ICDs for 6 months before and after ablation, the median number of VT episodes was reduced from 11 to 0; 67% of patients had a $>75\%$ reduction in the frequency of VT episodes. Procedure mortality was 3% with 6 of 7 deaths related to uncontrollable VT, and one due to tamponade with MI. There were no strokes or thromboembolic events. Non-fatal complications occurred in 7% of patients, including heart failure, increase in mitral regurgitation, and vascular access complications. The 1-year mortality was 15% with 38% of deaths due to ventricular arrhythmias and 35% due to heart failure. In multivariable analysis, lower LVEF, history of atrial fibrillation, recurrence of VT, greater number of RF lesions, and slower maximum VT cycle length were markers for increased mortality. The presence of a mappable VT was associated with decreased mortality. Predictors of recurrent VT included history of atrial fibrillation, history of heart failure, and greater number of inducible VTs.

The Euro-VT-Study performed catheter ablation using external irrigation and EAM in 63 patients at eight centres.¹⁰⁶ The population had a median of 17 VT episodes in the 6 months prior to ablation, age of 63 years, LVEF 0.28, and 67% had an ICD. An average of three VTs was inducible; 63% had unmappable VT and 37% had only mappable VT. At least one VT was ablated in 81% of patients; all inducible VTs were abolished in $\sim 50\%$ of patients. During follow-up of 6 months, 51% of patients remained free of any

recurrent VT. Although in patients with recurrences, the mean number of ICD therapies was decreased from 60 ± 70 prior to ablation to 14 ± 15 for the 6 months after ablation. There was no procedure mortality; one patient suffered prolonged cardiac arrest and died of progressive heart failure 2 months later. Non-fatal adverse events occurred in 5% of patients included groin haematomas and pericardial effusions that did not require drainage. There were no thromboembolic events. After an average follow-up of 12 months, mortality was 8% and was related to heart failure or cardiac transplantation in three patients, and incessant VT in one patient. The electrophysiological findings did not predict VT recurrence.

In a multicentre trial of 146 patients (82% of whom had coronary artery disease) who had mappable VT and ablation performed with an internally irrigated catheter; 54% were free of VT during an average follow-up of 8 months.¹⁶⁰ Of those with at least 2 months of follow-up, 81% experienced a $>75\%$ reduction in VT episodes. Complications included stroke in four (2.7%) patients, tamponade in four (2.7%) patients, and MI in one (0.7%) patient. Only one of the cardiac perforations seemed to be temporally associated with RF application. Procedure-related mortality was 2.7%.

The Substrate Mapping and Ablation in Sinus Rhythm to Halt Ventricular Tachycardia (SMASH-VT) multicentre study enrolled 128 patients with prior MI (average age 67 ± 9 years; LVEF 0.30–0.32) who were receiving an initial ICD for VF, unstable VT, or syncope with inducible VT.¹⁰² Patients were randomized to substrate-based ablation vs. a control group. There was no procedure mortality. During an average follow-up of 23 months, 33% of the control group, but only 12% of the ablation group, received appropriate ICD therapy for VT or VF. There was a non-significant trend to better mortality in the ablation group (9 vs. 17%, $P = 0.29$). Serial assessments of LVEF showed no evidence of a detrimental effect of ablation on ventricular function.

Prophylactic VT ablation in patients with ICDs implanted for primary or secondary prevention is investigational, and further trials are needed to assess this approach.

Catheter ablation can be immediately life-saving for patients with VT storm or incessant VT.^{105,262,317-319} Incessant or frequent VT is controlled acutely in over 90% of patients. During follow-up, 74–92% remain free of incessant VT or VT storm, although single episodes of VT recur in approximately a third of patients.

Recommendations

In patients with SMVT due to healed MI, methods for guiding ablation are now well defined. Even in the relatively ill populations referred after failing multiple antiarrhythmic drugs, procedure mortality and morbidity are acceptable. Ablation usually reduces the frequency of VT episodes, although isolated recurrences remain a risk. Although mortality from heart failure is a concern, this appears to be related largely to the severity of underlying heart disease. The use of mapping methods to maintain RF lesions in low-voltage regions of scar is recommended to reduce the

risk of damage to functioning myocardium. In view of these considerations, the task force members felt that ablation should generally be considered relatively early, before multiple recurrences of VT and repeated courses of drug therapy. Recommendations are summarized in Table 2.

Non-*ischaemic-dilated cardiomyopathy*

Sustained monomorphic ventricular tachycardia is not common in non-*ischaemic-dilated cardiomyopathies*, but 80% of those that occur are due to scar-related reentry, with the remainder due to bundle branch reentry or a focal origin.^{21,86,251,320} Scars are probably due to progressive replacement fibrosis. Compared with post-infarction VT, areas of scar are smaller, but patients who present with SMVT typically have multiple morphologies of VT inducible. Magnetic resonance imaging with delayed Gd enhancement and voltage mapping demonstrates that scars are often adjacent to a valve annulus.^{139,320} Transmural scar is rare and intramural scars are common. These features likely account for the general perception that ablation of VT is more difficult when compared with that in the post-MI population. When endocardial ablation fails, epicardial mapping usually shows that more extensive scar is present in the epicardium.^{21,86,139}

Catheter ablation employs the approaches for scar-related VT after exclusion of bundle branch reentry. Data are from small single-centre series.^{21,86,139} In a series of 19 patients with recurrent SMVT due to *dilated cardiomyopathy*, endocardial ablation abolished all inducible VT in 14 patients.¹³⁹ After a follow-up of $22 \pm$ months, five patients were alive without VT recurrence. In a series of 22 patients, epicardial mapping and ablation was performed if endocardial ablation failed.⁸⁶ Scar-related reentry circuits were identified in the endocardium in 12 patients and in the epicardium in all 7 who underwent epicardial mapping after failed endocardial ablation. At least one VT was abolished in 16 of 22 patients and all VTs were abolished in 12 of 22 patients. During a mean follow-up of 334 days, VT recurred in 46% of patients, one patient died of heart failure, and cardiac transplantation was performed in two patients. Ablation can be life-saving in patients with incessant VT or VT storm.^{262,266} In these small series, no serious complications were reported, although septal ablation produced anticipated AV block in one patient.

Recommendations for ablation are as stated for ablation of VT associated with structural heart disease in Table 2.

Surgically repaired congenital heart disease

Congenital heart defects occur in almost 1% of live births; 30–50% require surgery during early childhood.^{321,322} Life expectancy has steadily improved, but sudden cardiac death (SCD) remains the most common cause of late mortality.³²³ Ventricular scars from ventriculotomy or patches create the substrate for scar-related reentry.^{36,39,324} Focal VT has also been reported.¹²⁷ Myocardial hypertrophy occurs in a variety of malformations and also likely contributes to arrhythmia risk. The prevalence of VT after repair of Tetralogy of

Fallot ranges between 3 and 14%, with a risk for SCD estimated at 2% per decade.^{321,325-329}

The approach to catheter ablation of SMVT is as described for scar-related VTs.^{330,331} Physicians undertaking these procedures should be familiar with the anatomic complexities that are a major challenge. Knowledge of the details of the surgical repair, usually available in the operation report, is helpful. Imaging with angiography and echocardiography and integration of MRI or CT images to enhance the anatomic definition may be helpful.³³¹ Identification of the region of scar and a substrate mapping approach to identify channels has been described.³³¹

Data are from case reports and small patient series.^{104,127,330-337} Initial studies demonstrated feasibility of mapping and ablation, but late recurrences of VTs that were not observed at the time of the procedure and high recurrence in patients with unmappable VT were noted.^{330,336} A report using substrate mapping approaches after Tetralogy of Fallot or ventricular septal defect repairs described common isthmuses supporting reentry between the tricuspid or pulmonic valve annuli and scar or patch in the septum or RV free wall that could be targeted for ablation.³³¹ In 11 patients, 15 different VTs were inducible. Ablation abolished all inducible VTs. During an average follow-up of 30 months, 91% of patients were free of VT. In a series of 10 patients with Tetralogy of Fallot mapping with the non-contact electrode array demonstrated macroreentry in 11 of 13 induced VT.¹²⁷ Ablation was performed in eight patients, six of whom were free of VT during follow-up.¹²⁷ In these small series, no serious complications were reported.

Recommendations for catheter ablation are as stated for VT associated with structural heart disease in Table 2.

Right ventricular disease

Right ventricular diseases causing VT are infrequent. Arrhythmogenic right ventricular dysplasia/*cardiomyopathy* is probably the most common cause and has a prevalence of ~ 1 in 5000.³³⁸ Arrhythmogenic right ventricular dysplasia/*cardiomyopathy* is characterized by fibrofatty replacement of myocardium within the so-called triangle of dysplasia which encompasses the RV inflow, outflow, and apex. Septal and LV involvement has been described.³³⁸ Scar-related reentry is the most common cause of SMVT and is an important feature that helps distinguish these VTs from idiopathic RVOT VT, which is focal. Focal VTs in ARVD/C have been described,¹⁰⁰ although some of these cases may represent epicardial reentry with a focal endocardial breakthrough. Cardiac sarcoidosis with RV involvement can mimic ARVD/C.²⁷ Non-*ischaemic cardiomyopathy* and MI also cause some RV scar-related VTs.³³⁹

The methods for mapping and ablation are as for scar-related VTs; activation mapping, entrainment mapping, substrate mapping, and combined approaches have been used.^{23,28,100,201,315,340} As in infarct-related VTs, large scars and reentry circuits with extensive areas of abnormal electrograms, evidence of slow conduction, and bystander regions occur. Reentry paths are commonly located along the tricuspid

valve annulus or pulmonary annulus. A strategy aiming to transect an isthmus by extending ablation lesions from the annulus to a region of scar has been used.^{23,28,340} Irrigated RF ablation catheters are favoured as trabeculated and annular regions where cooling from circulating blood flow is low can limit power application. Attention to power titration and monitoring impedance is recommended due to concern for risk of perforation when ablating in the free wall of the RV. The reentry substrate is epicardial in an undefined, but important number of patients, consistent with the fact that ARVD/C involvement usually starts in the epicardium. Epicardial ablation has been successfully used after failure of endocardial ablation.^{135,288,341} Electrocardiographic criteria suggesting epicardial VT locations for the LV do not apply to RV tachycardias and pace mapping suggests that epicardial locations of OT VTs cannot be predicted from the QRS configuration, but Q waves or QS complexes suggest an epicardial origin for VTs in other locations.²⁸⁶

In reported series of RV scar-related VT, abolition of inducible VT is achieved in 41–88% of patients.^{23,28,100,103,126,315,340,342,343} During average follow-ups of 11–24 months, VT recurs in 11–83% of patients, with some series observing a significant incidence of late recurrences increasing with time.^{315,340} The variable outcomes likely reflect progression of disease, and the inclusion of different causes of myopathy, as most did not include genetic analysis, and different ablation strategies employed. In addition, epicardial mapping and ablation was generally not employed. Serious complications are infrequent, but the risk of perforation and tamponade is expected to be increased in areas where the RV is thinned, and this complication has been reported.¹⁷⁸

Catheter ablation in ARVC/D can reduce frequent episodes of VT but long-term follow-up has demonstrated a continued risk of recurrence.^{315,340} Recommendations for ablation are as stated for ablation for VT associated with structural heart disease in the Indications section above. Further studies are needed to clarify the role and benefit for epicardial mapping and ablation. There is also a need to better define the characteristics of patients who are likely to have long-term benefit from catheter ablation of VT.

Depressed ventricular function associated with frequent ventricular ectopy

Very frequent PVCs can result in a reversible form of cardiomyopathy, but cardiomyopathy can also cause PVCs; often, it is not clear that the PVCs are the cause of LV dysfunction. Negative inotropic effects of some antiarrhythmic drugs may also contribute to ventricular dysfunction. The critical number of PVCs and the time course required to cause a cardiomyopathy are not known. A PVC burden of >20% is present in most patients, but some patients have as few as 5% PVCs on a single 24 h Holter recording.^{344,345} The duration over which PVCs must be present to cause cardiomyopathy is not clear and difficult to assess because PVCs are asymptomatic in a substantial number of patients. Triggered activity and automaticity are probably the most

common mechanisms of focal PVCs in this setting. Reentry is unlikely in patients without scar, but has been documented in post-infarction models.³⁴⁶ Premature ventricular complexes in the setting of prior MI frequently originate from scar areas and may share QRS morphology features of post-infarction VT, suggesting that reentry might be their cause.³⁴⁷ Ablation is guided by activation mapping. Pace mapping can be used if PVCs are not frequent, but is probably less accurate.^{234,348,349}

Data are from small case series. In one series of consecutive patients with decreased LV function attributed to PVCs from a variety of different origins, the overall success rate of ablation was 82%.³⁴⁴ Premature ventricular complexes originated from the RVOT in half the patients; other sites of origin included the LV, the coronary cusps, and the pulmonary artery. Success is likely to be greater when only RVOT PVCs are present.³⁴⁵ Ventricular function improved following ablation.

Catheter ablation is recommended for patients with frequent PVCs or NSVTs when they are presumed to cause ventricular dysfunction. At the time of the ablation procedure, it is often not clear whether the frequent PVCs are causing LV dysfunction. Assessment of LV function during follow-up helps to clarify whether a cardiomyopathic process is present or whether PVCs resulted in a decline of LV function. To assess the contribution of PVCs to ventricular dysfunction, pharmacological suppression, such as by amiodarone therapy, may be considered, but the utility of this approach and duration of therapy required have not been defined. Multiple morphologies of PVCs are likely to reduce procedural success. The role for pre-procedural identification and quantification of a predominant PVC (for example, by performing a 12-lead Holter) warrants further study. In the absence of a predominant PVC morphology, medical management should be considered.

Bundle branch reentry

Bundle branch reentrant tachycardia (BBRT) accounts for ~5% of SMVTs induced during programmed ventricular stimulation in patients with heart disease.^{17,65,350} The reentry wavefront circulates retrogradely up one bundle branch (most commonly the left bundle) and down the other (most commonly the right bundle), giving rise to VT that usually has a typical left bundle branch block (LBBB) configuration that can be the same as the QRS configuration during sinus rhythm.^{17,65,350} Right bundle branch block configuration tachycardias occur when the left bundle is used antegradely, or are due to interfascicular reentry tachycardia involving both fascicles of the left-sided Purkinje system that may coexist with bundle branch reentry.^{17,67,355–357} In these RBBB tachycardias, right axis deviation indicates antegrade activation over left anterior fascicle and retrograde over the left posterior fascicle; and left axis deviation occurs when the circuit revolves in the opposite direction.³⁵⁸ The tachycardia cycle length is usually <300 ms; near syncope, syncope, or cardiac arrest are common presentations.

Substantial His-Purkinje system disease is usually present associated with ventricular dysfunction usually due to coronary artery disease, valvular heart disease, or cardiomyopathy.^{22,65,351,357,359-364} Cases due to sodium channel blockade with flecainide^{365,366} and isolated conduction system disease have been described. During sinus rhythm, the 12-lead ECG characteristically shows nonspecific interventricular conduction delay or LBBB and the HV interval is typically, but not always, prolonged.^{65,351,357,360,361,363,367} The VT can usually be induced by programmed RV stimulation; induction may occur with LV stimulation, short-long-short extra-stimuli sequences, isoproterenol infusion, sodium channel blockade, atrial stimulation, or an irregular rhythm from atrial fibrillation or flutter.^{65,357,368} Bundle branch reentrant tachycardia is confirmed by evidence linking the Purkinje system to the reentry circuit in His bundle and or right or left bundle recordings. During entrainment from the RV apex, the post-pacing interval-VT cycle length difference is typically 30 ms or less.³⁶⁹

Drug therapy is usually ineffective. Catheter ablation is a first-line therapy and successful in ~100%.^{357,360,361} The right bundle branch is the preferred ablation target. Even in patients with baseline LBBB, right bundle ablation does not usually produce heart block, but back-up bradycardia pacing is required in ~30% of patients.^{357,360,361,367}

Ablation of the left bundle branch may be considered when LBBB is present during sinus rhythm, but is more difficult and has risks of left heart catheterization. There is concern that LBBB may be more likely to adversely affect ventricular function than RBBB. Long-term outcome depends on the underlying cardiac disease. Despite successful BBRT ablation, many patients remain at risk of sudden death due to concomitant scar-related VTs and/or LV dysfunction. An ICD with or without cardiac resynchronization should be considered according to the current guidelines.

Special considerations for patients with implanted defibrillators

Patients undergoing catheter ablation of VT often have a previously implanted ICD or will undergo device implantation after ablation. For patients with incessant VT or electrical storm, an ECG can often be obtained to identify the QRS morphology of clinical monomorphic VT or the PVCs initiating PMVT. When the indication for ablation is recurrent ICD shocks or antitachycardia pacing therapies, a 12-lead electrocardiogram of the VT may not be available. In such cases, stored intracardiac electrograms provide a measurement of the VT cycle length, although only minimal clues to the morphology of the clinical VT, limiting ability to identify clinical VTs, particularly when multiple VT morphologies are inducible. It must be recognized that RF ablation may affect both the myocardial VT substrate and the pacing and sensing functions of an ICD; both of these aspects must be considered. Because programmed electrical stimulation and RF current are sensed by ICDs, these devices must be reprogrammed prior to the ablation procedure to prevent oversensing and unintended delivery of anti-

tachycardia therapies. Tachycardia detection zones must be programmed 'off' once the patient has been connected to an external defibrillator and personnel are available for monitoring of the patient. The ICD can still be used to deliver commanded shocks to terminate VT that is not interrupted by overdrive pacing. For patients who are pacemaker-dependent, the noise reversion response of the ICD should be programmed to an asynchronous mode before RF current is applied. For patients who are not pacemaker-dependent, the ICD is usually programmed to asynchronous noise reversion mode at a low pacing rate. Stimulation thresholds and intracardiac electrogram amplitudes should be measured before and after ablation to ensure appropriate pacing and sensing by the ICD. In addition, because RF current can result in an increase in the stimulation threshold of a previously implanted lead, the pacing thresholds should be measured and the stimulus amplitude programmed to anticipate a rise in threshold. If the electrogram amplitude is relatively low (<3 mV), induction of VF may be indicated to ensure effective sensing by the ICD after ablation. Following the ablation procedure, tachycardia detection must be reprogrammed 'on' and the antitachycardia therapies tailored to the results of final programmed electrical stimulation. Fluoroscopic confirmation of stable lead position after ablation may also be warranted. Some centres administer prophylactic antibiotics at the time of ablation in patients who have an ICD, even long after implantation; but many centres do not use antibiotic prophylaxis and infections related to catheter ablation appear to be rare.

Catheter ablation may affect several factors requiring consideration: (i) the indication for ICD implantation; (ii) the rate of VT that may require reprogramming of VT detection zones and maximum tracking rates for pacing;³⁷⁰ (iii) the addition or discontinuation of antiarrhythmic drugs that will affect the rate of recurrent VT or other arrhythmias and the defibrillation threshold;^{82,83,371} (iv) sensing of VT or VF by the ICD; (v) the response of VT to antitachycardia pacing algorithms; (vi) the requirement for reprogramming of ICD discrimination algorithms;³⁷⁰ (vii) the need for continued ICD therapy possibly allowing explantation of the device; and (viii) the potential loss of pacing if, for example, a pacing lead is dislodged or ablation in the vicinity increases pacing threshold.

In general, the results of catheter ablation of VT should have little influence on the indications for ICD implantation. However, the function of the ICD may influence the decision to proceed with catheter ablation. For example, biventricular pacing may sometimes induce incessant VT.³⁷² In this situation, the risks and benefits of resynchronization therapy must be weighed against those of catheter ablation. Most patients who have VT related to structural heart disease will continue to have a standard indication for ICD therapy for primary prevention.³⁷³ Even when all VTs have been rendered non-inducible by ablation, the recurrence rate remains substantial so that secondary prophylaxis remains indicated.^{374,375} One potential exception is when an ICD has

been implanted to treat idiopathic monomorphic VT such as from the RVOT or LVOT in the absence of structural heart disease. In these patients, explantation or deactivation of a previously implanted ICD may be considered if catheter ablation has successfully eliminated VT. However, an observation period is warranted after ablation and great care should be taken to exclude structural heart disease in these individuals.

VII. Idiopathic ventricular tachycardias

Idiopathic VT refers to VTs that occur in the absence of clinically apparent structural heart disease. These VTs occasionally occur in patients with structural heart disease, in whom the structural heart disease is not related to the VT. When frequent, they can be a cause of depressed ventricular function as a form of tachycardia-induced cardiomyopathy. Sudden death is rare, and therapy for idiopathic VTs is largely guided by symptoms. Ablation is a relatively effective option. Risks depend on the location of the VT origin. Indications for ablation are as summarized in the Indication section above, with addition discussion below.

Idiopathic outflow tract ventricular tachycardias

The region of RVOT and LVOT is the most common origin of idiopathic VT and PVCs, accounting for ~10% of all patients referred for evaluation of VT.^{14,376-388} More than 70–80% of these arrhythmias originate from the RVOT.³⁸⁹ Other origins include the pulmonary artery, near the bundle of His, the LVOT, the aortic sinuses of Valsalva, the coronary sinus (CS) and cardiac veins, the mitral and tricuspid valve annuli, and the epicardium.^{12,41,149,164,233,378,390-399} Although idiopathic focal OT-VT usually occurs in patients with no structural heart disease, MRI has shown subtle areas of diminished wall motion and suggested that mild structural abnormalities may be present.⁴⁰⁰⁻⁴⁰⁵ These tachycardias have a focal origin, and findings consistent with triggered activity (see the Mechanism section), including initiation by burst pacing and isoproterenol administration.^{377,400,406}

Idiopathic focal OT-VT typically presents between ages 20 and 50 years and occurs more frequently in women;⁴⁰⁷ hormonal triggers may influence occurrences.^{381,408} There are two typical forms: exercise- (stress-) induced VT and repetitive monomorphic VT occurring at rest. Repetitive salvos of NSVT are frequent, comprising 60–92% of reported series, but incessant VT occasionally occurs. Paroxysmal sustained VT, separated by relatively long intervals of infrequent premature ventricular beats is less common.⁴⁰⁹ Episodes tend to increase in frequency and duration during exercise and emotional stress. Thus, an exercise test may provoke focal OT-VT either during exercise or in the recovery phase. In a significant number of patients, exercise suppresses the arrhythmia.^{5,410}

The typical QRS morphology during idiopathic focal OT-VT shows LBBB configuration with an inferior (right or left) axis. Premature beats or the first beat of VT usually has a relatively long coupling interval to the preceding QRS-com-

plex.⁴¹¹⁻⁴¹³ The QRS duration is usually <140 ms and a QRS duration >120 ms in lead I suggests RV dysplasia rather than idiopathic VT.⁴¹⁰ Ventricular tachycardia is monomorphic; however, the QRS morphology may vary slightly during tachycardia. Multiple distinct VT morphologies are very rare and should raise the suspicion that a scar-related VT, rather than idiopathic VT, is present.^{342,379,382,414}

Although idiopathic focal OT-VT has a benign course, potentially malignant forms of VT that resemble idiopathic focal OT-VT may also arise from the OT region, including VT in ARVC,^{342,376,415,416} polymorphic catecholaminergic VT,³⁸⁸ VT/VF in Brugada syndrome,¹⁴ and also idiopathic PMVT/VF.^{380,387,400,413,417} It is important to differentiate these arrhythmias from idiopathic focal OT-VT. All patients presenting with OT-VT require an evaluation for organic heart diseases or genetic syndromes associated with sudden death. The ECG during sinus rhythm is usually normal, but ~10% of patients with OT-VT show complete or incomplete RBBB.⁴¹⁰ T-wave inversion in the anterior precordial leads suggests ARVD.⁴¹⁸ A Brugada type ECG, findings of reduced LV or RV function, PMVT or multiple VT morphologies, a history of recurrent syncope, or a family history of SCD mandate further detailed evaluation. An exercise test and cardiac imaging (usually at least echocardiography) should be done in all patients. Left and/or right heart catheterization may be warranted. Invasive electrophysiological study is usually not necessary to establish a diagnosis.

The success of ablation depends on the presence of spontaneous or inducible VT or PVCs at the time of the procedure. All antiarrhythmic medications should be discontinued for at least five half-lives before the procedure. Sedation can decrease spontaneous or inducible arrhythmia, but in many patients, mild sedation and adequate analgesia do not prevent spontaneous or provoked VT.³⁸¹ In addition to diagnostic electrode catheters at the RV apex, assessing activation on catheters at the His bundle position and in the great cardiac vein via the CS can be helpful in suggesting the origin.⁴¹⁹ If spontaneous PVCs or VT are absent, programmed stimulation and burst pacing with or without isoproterenol infusion should be performed. Careful catheter manipulation during mapping should seek to avoid mechanical trauma that may transiently abolish the arrhythmia.

Analysis of the surface ECG morphology of PVCs or OT-VT is a cornerstone to localize the site of origin.^{5,385} Recording of spontaneous or induced OT-PVC or OT-VT in the EP laboratory is important to direct the procedure and guide pace mapping. Electrocardiographic recordings from outside the EP laboratory may not allow sufficient precision for pace mapping due to differences in patient posture and lead position during the recording. Premature ventricular complexes with the same morphology as VT are an acceptable target if VT is not inducible. In the absence of spontaneous or inducible clinical arrhythmia, catheter ablation should be avoided.

Precise localization of the VT origin from its QRS morphology is limited by the close anatomic relations of RVOT,

LVOT, and great vessels.^{2-4,6,41,349,384,389,391,396,398,410,420-424} Ventricular tachycardia arising from RVOT typically shows an R/S transition zone in the precordial leads at V4, whereas an R/S transition at V1 or V2 indicates an LV origin.^{6,384,391,410} An R/S transition at V3 is compatible with RV or LV origin.^{4,6,41,384,391,414,421,422,424-426} A longer time to maximum deflection in the precordial leads suggests an epicardial origin.²⁹³ A broad R-wave in V1 or V2 suggests an aortic cusp origin.^{41,427}

Precise localization for ablation is guided by activation mapping, pace mapping, or a combination of both methods. Mapping should begin in the RVOT (including the pulmonary artery), followed by the great cardiac vein, and then LVOT and aortic cusps. Epicardial mapping is occasionally necessary. Most epicardial OT-VTs originate at or close to the superior CS and the cardiac veins.^{164,293,392,427} Mapping of the great cardiac vein is recommended before epicardial mapping by pericardial puncture.

Right ventricular outflow tract tachycardia

The focal VT origin can be identified from activation and/or pace mapping.^{4,381,385,410} Systematic point-by-point activation mapping is the initial preferred technique.^{233,234,385,409} Some investigators use three-dimensional EAM systems to assist in relating the anatomy to the mapping data.^{4,124,125,233,381,385,428-430} In the RVOT, bipolar electrograms typically have normal amplitude (e.g. >1.5 mV) and are sharp, without fragmentation. Activation at the site of successful catheter ablation precedes the onset of the surface QRS complex by 10–60 ms.^{379,389,390,431,432} The bipolar electrogram may display high-frequency low-voltage activity preceding the main local ventricular electrogram component. Ventricular tachycardia occasionally originates from muscle bundles extending along the pulmonary artery, where low-amplitude signals are recorded.^{4,396} Unipolar electrograms show a sharp QS-morphology with a sharp intrinsic deflection indicating the activation moving away from the mapping electrode.⁴³³

Although activation mapping is the strategy of first choice, pace mapping can be used to identify a region of interest and then refine position based on activation, and can be the major guide to the ablation site when spontaneous arrhythmia is infrequent. Pace mapping should be done at the VT rate. A site where pacing exactly reproduces the 12-lead ECG of the spontaneous or induced VT should be sought.^{385,434} The spatial resolution of pace mapping is limited and in some patients a perfect pace map is seen at sites up to 2cm away from the VT origin.^{233,234,349,381,385} Pacing at stimulus strengths only slightly greater than threshold is desirable to avoid capture over a large area that may reduce accuracy.

Radiofrequency ablation with solid 4 mm tip electrodes at maximal temperatures of 50–70°C and power settings of ≤50 W is usually sufficient for ablation when mapping is adequate (see the Technologies section). Use of 8 mm electrodes with higher power or irrigated electrodes is usually not necessary. Avoiding steam pops from high-power

ablation is particularly desirable to avoid perforation when ablation is performed in the RVOT.

There are no controlled or multicentre trials of ablation. In reported case series, acute success rate of RF catheter ablation of RVOT-VT is 65–97% and typically exceeds 80%; recurrence of arrhythmia has been reported in up to 5% after acutely successful ablation.^{2,6,178,342,349,381,390,394,395,406,435,436} Failure is usually due to inability to induce the arrhythmia for mapping. Complications are rare, but perforation and tamponade are reported and ablation of foci near the His bundle region can result in heart block.³⁹⁸ The leftward posterior aspect of the RVOT is only 4 mm from the left main coronary artery, such that there is a theoretical risk of coronary artery injury with ablation in that aspect of the RVOT and pulmonary artery, that would likely be increased with the use of high-power, irrigated ablation.¹⁵²

Left ventricular outflow ventricular tachycardias

Left ventricular outflow tachycardias can originate from the superior basal region of the left interventricular septum, LV free wall, aortic sinuses of Valsalva, or the LV epicardium. Small case series demonstrate feasibility of ablation for most of these VTs and suggest acceptable risk. However, left heart catheterization is required, introducing risks of thromboembolism, coronary arterial injury, and aortic valve injury.

Left ventricular outflow tract tachycardias that originate from the endocardium near the aortic annulus have a QRS with an inferior axis and may have an earlier precordial transition to positive R-wave, sometimes with prominent R-waves in V1 or V2, when compared with RVOT tachycardia.^{4,378,406,437-439} The approach to mapping and ablation is similar to that for the RVOT tachycardias. Heart block, aortic valve, and coronary artery injury are potential risks. Feasibility of ablation has been shown in small case series and anecdotal reports.^{4,378,406,437-439}

Aortic cusp ventricular tachycardias

Ventricular tachycardia originating from extension of ventricular myocardium above the aortic annulus that required ablation from within the sinuses of Valsalva accounted for 17 and 21% of idiopathic OT-VTs in two recent series of 155 and 352 patients, respectively.^{2,440} The majority are ablated from the left coronary cusp, followed in frequency by the right coronary cusp, the junction between the right and left coronary cusp, and rarely the non-coronary cusp. Activation mapping typically shows a two-component electrogram with the earliest deflection preceding the QRS complex by an average of 39 ms, but sometimes >50 ms.^{41,427,440,441} Pace mapping in the aortic sinus may require high output and is less likely to reproduce the VT QRS compared with pace mapping for endocardial VTs.

Small case series have shown feasibility of successful ablation without reported significant complications.^{41,427,440,441} The potential for acute occlusion of the left main or right coronary arteries is a major concern. The proximity of the coronary ostia to the ablation site must be defined by coronary

angiography or ICE by an experienced operator.⁴²² Sites of successful ablation are typically >8 mm below the coronary artery ostia. Injury to the aortic valve is theoretically possible.^{163,421} Titration of energy beginning at low power is reasonable.

Epicardial outflow tract ventricular tachycardias

Percutaneous epicardial mapping and ablation is useful in selected patients. Epicardial foci cause VTs with a longer interval from QRS onset to earliest maximal deflection in the precordial leads, consistent with late access of the wavefront to the endocardial Purkinje system.²⁹³ The VT focus may be adjacent to the great cardiac vein that can be cannulated via the CS, allowing successful ablation via this route.^{164,392,442} These VTs have also been ablated via percutaneous pericardial access.²⁹³ The risk of coronary injury when the focus is adjacent to a coronary artery is a major concern. The overlying left atrial appendage can also be an anatomic obstacle to ablation.⁴³⁹ When proximity to epicardial coronary artery precludes catheter ablation, a direct surgical approach can be an option.²⁹³ Feasibility of ablation has been shown in small case series and anecdotal reports, but risks and benefits are not well defined.

Mitral annulus ventricular tachycardia

Focal VT from the mitral annulus accounted for 5% of idiopathic VTs in one series.² Ventricular tachycardia has RBBB or RS pattern in V1 and monophasic-R or RS pattern in leads V2–V6. Endocardial ablation is usually successful; ablation from within the CS may occasionally be required.^{2,395} Feasibility of ablation has been shown in small case series and anecdotal reports, but risks and benefits are not well defined.

Other locations

Successful ablation of focal idiopathic VTs originating from the tricuspid annulus, papillary muscles, and occasionally at other ventricular sites has been described in case reports and small series.^{3,149,394}

Intrafascicular verapamil-sensitive reentrant tachycardia

Intrafascicular verapamil-sensitive reentrant tachycardia typically presents as exercise-related VT between the ages of 15 and 40 years; 60–80% of patients are male.^{2,69,123,383,443–446} Ventricular tachycardia has an RBBB configuration with rS complexes in the mid-precordial leads. The mechanism is reentry in or near portions of Purkinje fascicles of the left bundle. More than 80% of these VTs have exits near the posterior fascicles of the left bundle, causing a superior frontal plane axis. Occasionally, VT has an inferior axis, suggesting an exit in the vicinity of the anterior fascicle. An area of rounded-appearing potentials in diastole during VT and sinus rhythm is present in the inferoseptal region that appears to indicate a slow conduction region that is sensitive to verapamil appears to be involved in the circuit.^{93,447} Ablation targets sharp potentials near the circuit exit or the diastolic potentials.^{69,93,123,383,444–446,448} Mechanical trauma

from catheter manipulation often terminates VT and prevents reinitiation. Ablation then targets the site of mechanical termination, low amplitude, or diastolic sinus rhythm potentials, or creates a line of lesions through this region.^{93,123,443}

Of 103 patients reported in 10 series, the overall success rate of ablation was >95%.^{69,123,383,443–446,448} Although complications related to left heart catheterization and are expected, no serious complications were reported. Left posterior hemiblock has been observed when a line of RF lesions was placed through the posterior septal region.¹²³

Polymorphic ventricular tachycardia and ventricular fibrillation

Polymorphic VT and VF may present as an arrhythmia storm and, in this uncommon instance, may be considered for catheter ablation. The prevalence of VT/VF storms in ICD patients is ~20%,⁴⁴⁹ whereas idiopathic VF is estimated to represent 5–10% of SCD cases.^{450–452} β -Adrenergic blockers, various antiarrhythmic drugs including amiodarone, procainamide, and lidocaine and even general anaesthesia can be effective.^{453,454} Catheter ablation can play a crucial role when drugs fail and has been described for the following conditions: post-MI,³¹⁷ Brugada syndrome,³⁸⁰ long QT syndrome,³⁸⁰ RVOT ectopy,⁴⁵⁵ and idiopathic VF.⁴⁵⁵

These PMVTs likely have various mechanisms. After MI, afterdepolarizations and triggered activity from Purkinje fibres in the infarct region may cause premature ventricular beats that initiate PMVT/VF.³¹⁷ In the Brugada and long QT syndromes, and some rare idiopathic VF patients, closely coupled monomorphic ectopic beats from the LV or RV Purkinje network or from the RVOT may lead to PMVT/VF.³⁸⁰ Patients with idiopathic VF typically have isolated premature ventricular beats, best appreciated immediately following resuscitation. Premature beats with a positive QRS morphology in lead V1 are from the LV and tend to be polymorphic but with a characteristically short QRS duration often in the range of 115 ms. Conversely, premature beats with a negative QRS morphology in lead V1 are typically from the RV and have a significantly longer QRS duration.

Feasibility of ablation targeting the initiating PVCs that trigger PMVT/VF has been demonstrated in small series.⁴⁵⁵ Mapping requires frequent ventricular ectopy and is best performed at the time of arrhythmia storm. Ablation is not feasible when triggering ectopic sources cannot be identified. In the absence of arrhythmia storm, provocative manoeuvres including the use of isoproterenol or extrastimuli are not usually helpful. Pace mapping can be used in cases of monomorphic ventricular ectopy where a clear 12-lead recording of the ectopic beat has been recorded. Activation mapping is the most widely used technique. Targeting ectopy from the Purkinje system, in the syndromes above or after MI, a low-amplitude and high-frequency signal (Purkinje potential), which precedes and is closely coupled to the ventricular signal, is recorded at the successful site. The

end-point of ablation is the abolition of the local Purkinje potentials and suppression of the targeted ventricular ectopic beats including during provocation with isoprenaline and pacing. Mapping and ablation of triggers in the RVOT is identical to that for idiopathic OT tachycardias described above.³⁸⁰

The reported series demonstrate feasibility. However, these results were obtained in small series from expert centres. The success rate for ablation of VF storm following MI was 100% in four patients at 5, 6, 14, and 33 months follow-up.³¹⁷ In a multicentre study of 27 patients with idiopathic VF and malignant RVOT VT, 89% of patients were free from recurrent PMVT/VF at 24 months (27 patients).⁴⁵⁵ In seven patients with PMVT related to Brugada and long QT syndromes, all remained free of PMVT/VF during 17 months of follow-up.³⁸⁰ There were no serious complications.

Catheter ablation is recommended for recurrent PMVT and VF that is refractory to antiarrhythmic therapy when there is a suspected trigger that can be targeted for ablation. This is a challenging procedure and should be performed only in experienced centres. Success is facilitated by very frequent ventricular ectopy to facilitate mapping, often necessitating that the procedure be performed emergently when the arrhythmia is active.

VIII. Training and institutional requirements and competencies

Catheter mapping and ablation in patients with potentially life-threatening ventricular arrhythmias is a challenging procedure that requires advanced technical and manual skills. Strategies, methods, and technology are evolving rapidly, and training and operator level requirements will change over time. Ventricular tachycardia ablation procedures should be performed in experienced, adequately equipped centres that have a dedicated electrophysiology programme that offers appropriate patient assessment and selection, treatment strategies, and follow-up after ablation. The procedure should be performed by a fully trained cardiac electrophysiologist. Technical skills are even more demanding for epicardial VT ablation procedures, which should only be performed by physicians with considerable experience with VT ablation.

Training requirements

In comparison with other ablation procedures, VT ablation procedures are more often performed in patients with serious underlying heart disease and are associated with a significant risk of complications and possibility for haemodynamic deterioration.¹⁰⁵ Physicians entering training programmes that include VT ablation must be familiar with current cardiopulmonary resuscitation (CPR) techniques. Trainees should be familiar with ablation procedures for supraventricular tachycardias and should comply with the requirements specified in the American College of Cardiology/American Heart Association 2006 update of the clinical

competence statement on invasive electrophysiology studies, catheter ablation, and cardioversion.⁴⁵⁶

Training for VT ablation should include the following:

- (i) Selection of patients who may benefit from an ablation procedure.
- (ii) Thorough knowledge of the anatomy of the ventricles, the valvular apparatus, and the coronary vasculature.
- (iii) Knowledge of the different mechanisms potentially causing ventricular arrhythmias.
- (iv) Knowledge of other treatment modalities (including antiarrhythmic drugs, implantable defibrillators, and surgery).
- (v) Cardiac haemodynamics and the potential deleterious haemodynamic effects of ventricular arrhythmias.
- (vi) Recognition, prevention, and management of complications.
- (vii) Current strategies, methods, and technology for VT ablation procedures, including state of the art imaging techniques.
- (viii) How to perform structured patient screening, selection, treatment, and follow-up.
- (ix) Technical skills.

Selection of patients who may benefit from an ablation procedure

Although VT ablation is an option for an increasing number of patients with a variety of cardiac diseases and range of disease severities, the procedure has significant risks and many patients are not candidates. The trainee must learn how to assess risks and benefits in selecting patients for VT ablation procedures. Training must include counselling patients about the risks and potential benefits of ablation as well as alternative therapies. Patients should only be treated after considering all possible treatment options.

Thorough knowledge of the anatomy

Detailed knowledge of the anatomy of the ventricles (including the conduction system), the valvular system, and the coronary arteries and veins is mandatory for performing VT ablation procedures. This knowledge is necessary to obtain safe access to the area of interest, because VT may arise from anatomically complex regions and because anatomy is an important determination of risks to the vasculature, His-Purkinje system, coronary arteries, phrenic nerves, and valves.

Knowledge of ventricular arrhythmia mechanisms

The VT mechanism often determines the mapping approach. Knowledge of VT mechanisms is necessary, including knowledge of the different pacing and pharmacological manoeuvres that help discriminate between the different mechanisms. Expert knowledge in interpretation of the 12-lead ECG, not only to discriminate between SVT and VT, but also to determine potential sites of VT origin and to be able to interpret pace-mapping data, is required.

Knowledge of other therapies (including antiarrhythmic drugs, implantable defibrillators, and surgery)

Many patients will not be suitable candidates for VT ablation or may be adequately treated with other therapies. Furthermore, the patient's course may evolve to require combinations of therapies. Detailed knowledge of pharmacological, surgical, and device-based therapies for VT is required. Ventricular tachycardia ablation should be part of an integrated treatment protocol for patients with structural heart disease. The trainee should be taught to work with surgeons, interventional cardiologists, and heart failure specialists with the goal of achieving the best outcome for the patient.

Assessment of cardiac performance and the potential deleterious effects of ventricular arrhythmias on haemodynamic stability

Haemodynamic consequences of ventricular arrhythmias vary from minimal to catastrophic. The ability to assess haemodynamics and an understanding of the potential effects of VT are required. Knowledge and experience with basic CPR techniques are required. The trainee should be able to monitor vital signs and to recognize signs of haemodynamic or respiratory deterioration that may occur during the mapping and ablation procedures.

Recognition, prevention, and management of complications

Complications may occur unexpectedly during or after VT ablation procedures, including cardiac tamponade, thromboemboli, and electrical storm, and require prompt recognition and therapy. The trainee must acquire extensive knowledge of the potential complications, their presentations, and treatments.

Strategies, methods, and technology in current VT ablation procedures, including the use of state of the art imaging techniques

Understanding of the different systems for imaging, mapping, and ablation (see the Technology section) is required to select among them and to plan and implement their appropriate use according to the anticipated type of heart disease and VT. Knowledge regarding the risks of radiation from fluoroscopic imaging, and methods to limit radiation exposure according to the ALARA principles are required.⁴⁵⁷ Preferably, the trainee should follow a certification programme before starting the training (according to local laws). Knowledge of the operational aspects of mapping systems is required.

Performance of structured patient screening, selection, treatment, and follow-up

For optimal patient treatment, the trainee must acquire knowledge for implementing a structured screening, selection, treatment, and follow-up programme. This should include knowledge of the evaluation required to assess the type and severity of heart disease and associated diseases, and factors that increase the risk of ablation procedures,

including the use of cardiac diagnostic imaging techniques. Ventricular tachycardia ablation procedures should be performed in a structured manner that seeks to limit the risk of complications and to achieve an optimal outcome. In order to evaluate the results of the procedure, follow-up should also be performed in a structured manner.

Technical skills and maintenance of experience

Ventricular tachycardia ablation procedure is a complex task requiring significant technical skills. It should be performed as part of an integrated treatment plan by physicians able to integrate anatomic and electrophysiological data obtained from different mapping and imaging systems.

An ongoing experience with the procedure is required to maintain competence and incorporate advances in knowledge as the procedure evolves. Electrophysiologists and centres should be discouraged from performing VT ablation if they do not maintain a significant experience with the technique. Furthermore, optimal treatment of many VT patients requires involvement of multidisciplinary group that may also include interventionalists, cardiac or thoracic surgeons, imaging specialists, and heart failure specialists.

Institutional requirements

A fully functional laboratory for ablation of VT includes a dedicated work space, typically between 400 and 600 square feet, and often an anteroom housing the programmed stimulator, recording system, and dedicated mapping system. A positive pressure ventilation system with air exchange cycles meeting any mandated regulations for air exchange is a standard operating requirement for many laboratories. Standard medical gases, accessible from an outlet console, should include oxygen and compressed air (for a ventilator), as well as a vacuum line for suction. Laboratories should be equipped with single or biplane fluoroscopy system to facilitate mapping; these systems should have capability for cinefluoroscopy and cineangiography. The latter is particularly helpful for outlining the coronary ostia for VTs that originate from the aortic cusps or for delineating the coronary anatomy prior to epicardial ablation. The availability of digital-pulsed fluoroscopy at low pulse frequencies significantly reduces radiation exposure, as does a flat panel detector and the presence of exposure attenuation filters.^{458,459} Radiation scatter to the operator may also be reduced by lead glass, lead curtains, whole-body shields, and the use of sterile disposable x-ray shields.⁴⁶⁰

All laboratories should be equipped with at least one, and preferably two biphasic DC defibrillators. In the event that one defibrillator fails, due to premature battery depletion or random component failure, or that multiple rapid shocks are required, immediate accessibility to a second defibrillator can be life-saving. In many laboratories, one defibrillator is connected to the patient via disposable defibrillation pads, whereas the other defibrillator serves as a backup device.

A physiological recorder should be located adjacent to the patient, for nursing or technician access, and have the capability to monitor pulse oximetry, non-invasive, and

intra-arterial blood pressure, and to record one or more ECG channels.

A programmed stimulator should have a constant current source, at least two and preferably four output channels and the capability of synchronizing its output to the native or paced rhythm. EP laboratory recording systems have evolved from analog to digital storage media, with DVD or network storage being the current preferred medium. Current digital recording systems are capable of continuously recording a 12-lead ECG simultaneously along with intracardiac electrograms from three or more catheters ECG throughout the study. Availability of at least 32 recording channels is desirable.

Display monitors for real-time intracardiac and ECG recordings, and for review purposes are essential requirements. Some laboratories may also prefer monitors for additional display of electroanatomical maps and intracardiac echocardiographic images.

Each laboratory should have a dedicated RF generator unit that is designed for catheter ablation. The capability for irrigated or cooled-tip RF ablation is also desirable.

An EAM system should be available for mapping and ablation of scar-related VTs.

Intracardiac echocardiography can be helpful in ablation of VT by defining LV structures, such as papillary muscles and false tendons, and monitoring in real-time, proximity to coronary ostia when ablation is performed in the coronary cusps.

Personnel

Ventricular tachycardia ablation procedures are complex and should be carried out with trained personnel, typically with either two nurses or a nurse and a technician present throughout the procedure.⁴⁶¹ The credentialing requirements for personnel depend on the institution's specific requirements. At least one person should be expert in monitoring sedation and administering drugs. At least two people in attendance should be proficient in assessing vital signs, using a DC defibrillator and performing CPR. An anaesthesiologist or nurse anaesthetist should be available for consultation or assistance if needed. Someone expert in operating the mapping systems that are used should be present. The institution should have a biomedical engineering department responsible for the integrity and maintenance of the equipment and available for troubleshooting.

A physician to perform coronary angiography to delineate coronary anatomy for epicardial and aortic sinus ablation procedures, and to insert an intraaortic balloon pump if the need arises, should be available. A cardiac or thoracic surgeon should be available in the event that sternotomy with cardiopulmonary bypass is required.

IX. Clinical trial considerations

Needs

Whereas several large randomized multicentre trials for ICD therapy assessing mortality have been performed, most knowledge of catheter ablation outcomes derives from sin-

gle-centre studies. In most cases, these studies reflect the experience of large academic centres, the outcomes of which may or may not be replicated by smaller centres. The inherent design of such studies leave many questions unanswered. This section will address clinical trial considerations for the population of patients with scar-related VT/VF. The members of this task force feel that studies in idiopathic VT are difficult to conduct, since ablation of idiopathic VT is well established as a standard therapy for many VTs.⁴⁵⁴ Furthermore, idiopathic VTs are relatively benign and comparative trials on morbidity or mortality would require large patient numbers.

At present, very limited data establishing the long-term impact of catheter ablation of VT/VF on major morbidity and mortality are available. There are no randomized multicentre trials with mortality as the primary endpoint comparing catheter ablation with either best medical antiarrhythmic or ICD treatment. There are many questions that are left unanswered by the present data for ablation of VT in structural heart disease. Some of the major questions include:

- What is the long-term efficacy of catheter ablation?
- What are the comparative success rates of various drug and ablative therapies?
- What are the outcomes of different ablation strategies such as ablation at critical isthmuses vs. ablation at exit sites and other targets?
- Should ablation target the epicardium first in some patients and can these patients be identified?
- What is the impact of ablation on ventricular size, morphology, and function? Can ablation of VT slow or improve ventricular remodelling?
- Does the benefit of VT ablation vary for patients with different underlying cardiac and non-cardiac diseases?
- Does ablation improve long-term morbidity and mortality?
- Can ablation eliminate the need for an ICD? If so, in which patients? For different diseases and severity of disease, what density or frequency of VT warrants ablation? Are there patients who should receive prophylactic VT ablation after ICD implantation, before recurrence of VT?
- Is ablative cost-effective relative to other arrhythmia therapies?
- What are the safety and efficacy outcomes of other ablation technologies such as intracoronary alcohol injection, cryoablation, ultrasound, and laser energy?

Investigational studies: current and future

These unresolved issues provide a strong incentive to conduct clinical trials specifically designed to answer critical questions. These include:

- (i) sufficiently powered, randomized mortality studies;
- (ii) multicentre outcome trials;
- (iii) industry-sponsored device approval studies; and
- (iv) carefully designed single and multicentre registry studies.

Mortality trials

Although large, multicentre randomized clinical trials are expensive and require years for completion, they are required to determine the impact of therapy on mortality and other long-term outcomes. A randomized trial design is most likely to provide an unbiased understanding of the outcomes of ablative intervention and to provide information that can be extrapolated to the largest possible number of patients. These studies are appropriately held to a higher clinical trial standard or burden of proof and should require the comparison of ablative therapy against ICD therapy, which has been shown to be superior to the best available drug therapy. Because ICDs have not been demonstrated to reduce mortality in patients with SMVT and LVEF >0.35, we believe that a trial of catheter ablation vs. ICD in this patient population should be considered. At publication, however, no such studies have been conducted.

Multicentre outcomes trials

The disadvantage of mortality studies is the accompanying cost and length of time required for completion. Knowledge will be more immediately advanced by smaller multicentre trials that can provide answers to specific questions more quickly. These trials have often been performed to support the applications of new catheter designs for clinical use. These trials could be used to compare outcomes, including quality of life, for different diseases, different ablation strategies, and according to the frequency of VT episodes. If conducted in consortium research groups, these trials could provide outcome data applicable to a wide range of patients, without the limitations of single-centre studies. Particularly, since episodes of VT are known to have a negative impact on quality of life and have been associated with markers of sudden death, trials that evaluate the impact of ablation on the frequency of VT are clinically relevant.⁸⁵⁻⁸⁹

Industry-sponsored device approval studies

The number of prospective, randomized, clinical trials to evaluate the safety and efficacy of VT ablation using investigational catheters and systems as part of FDA and other regulatory agency approval processes is presently very limited. Compared with AF ablation, the need for VT ablation, as perceived by industry, is considered to be rather small; and there has been comparatively little technological innovation introduced in recent years. Studies conducted for this purpose are often limited by short follow-up durations, and restrictive inclusion and exclusion criteria. Such studies could be substantially streamlined by the elimination of requisite randomized comparisons with drug therapy. One of the major problems of such trials is defining a meaningful endpoint, particularly if no control arm is included. A pre-specified reduction in the number of VT episodes after is such a potential endpoint, but requires definition of matched pre- and post-ablation time intervals. A 75% reduction of VT episodes as has been reported in post hoc analyses from some trials could be a clinically relevant endpoint.¹⁷⁰ Development of statistical methods to facilitate analysis of this type of data is of interest.

Furthermore, randomization against an accepted state of the art ablation catheter may be sufficient for assessing efficacy and safety in device approval studies. Sham procedures for control groups are not recommended.

Ablation registry studies

The use of registries to collect ablation data should be encouraged. Two former surveys of catheter ablation including patients with VT have provided insight into ablation outcomes outside of the largest academic centres. In this regard, the registry format discloses outcomes of ablation therapy as it is actually performed in practice. Importantly, registries can be sufficiently large to provide efficacy and safety information in subgroups of rare diseases that cause VT, such as ARVD, and more common diseases that infrequently cause VT, such as hypertrophic cardiomyopathy or valvular heart disease. Registries can also clarify the frequency and nature of uncommon complications.

Standards for reporting outcomes in clinical trials

A clear understanding of the safety and efficacy of VT ablation is impeded by the highly variable definitions and endpoints used in the reports of single-centre clinical experience. There are substantial differences in treatment modalities, endpoints of acute and long-term success, follow-up, redo and cross-over treatments, and accounting of adverse events. To allow comparisons between ablation technologies and/or techniques, standards for data reporting should be defined and followed. Furthermore, a standard for the minimum data required for all VT ablation reports should be defined. Minimum data reported should include the procedural outcome and clinical outcome. Standardized reporting of these data will facilitate comparisons of outcomes for different patient groups and centres. For example, the immediate procedural outcome is often variably reported as inducibility or absence of inducibility of the clinical VT or any VT. Even if this information can be interpreted, variations in stimulation protocols (including the number of extra-stimuli, pacing sites, and use of isoproterenol) among centres limit comparisons between different centres and reports.

Assessment of efficacy based on symptoms reported by the patient is limited as with all other arrhythmias. Standardization of follow-up is facilitated by the presence of ICDs in most patients with heart disease; however, follow-up times reported in different studies range from 6 months to 2.5 years. Furthermore, consideration needs to be given to the capacity for data storage in ICDs, which is limited and differs among devices. Full electrogram documentation may be retrievable for some events, but for others, details may be erased or not recorded, such that only the time, VT rate, and therapy can be obtained. A protocol should be in place for analysis of arrhythmia recurrences in the event of ICD storage overload.

The definition of a successful outcome also has varied, with some studies requiring freedom from the clinical VT, from a slow VT or from any VT in the absence of antiarrhythmic drug therapy, whereas other studies require freedom from VT or a reduction in VT/VF burden independent of drug therapy. Most commonly, freedom from VT at any particular time point has been analysed from time to first recurrence using life-table

Table 3 Standards for reporting results of catheter ablation for VT

-
- (1) Baseline clinical characteristics**
- (A) Characteristics of spontaneous arrhythmias**
1. Duration over which episodes of VT/VF have occurred
 - The number of episodes within the preceding year; or other defined interval
 - Specify whether VT frequency is determined from an implanted device.
 2. The type of VT as monomorphic, polymorphic, sustained, stable or unstable, and method(s) of termination.
 3. Indication of whether patients have previously failed pharmacological therapy due to VT recurrences or inability to tolerate drug therapy
- (B) The type and severity of underlying heart disease including right and left ventricular function, presence of coronary artery disease**
- (C) Significant comorbidities that may influence mortality including**
- Hypertension
 - Diabetes mellitus
 - Atrial fibrillation
 - Heart failure
 - Renal insufficiency
 - Peripheral arterial occlusive disease
 - Prior stroke
- (D) Use of medications that are known to influence outcomes including:**
- Antiarrhythmic medications
 - Beta-adrenergic blocking agents
 - Other therapies for heart failure or ventricular dysfunction (e.g. angiotensin-converting enzyme inhibitors, aldosterone antagonists).
- (2) Mapping and ablation**
- (A) The protocol for initiation of VT should be described in detail**
- Sites of stimulation
 - Basic drive cycle lengths (with or without sinus rhythm)
 - Maximum number of extrastimuli
 - Use of isoproterenol
 - In general, stimulation should include two RV sites with at least three extrastimuli.
- (B) The mapping criteria for the identification of the ablation target**
- (C) The method of ablation**
- Type of catheter
 - Energy source, power, and duration of energy application
- (D) The results of the stimulation protocol repeated after ablation**
- The stimulation protocol should be the same as before ablation and completed if no VT is induced
 - The reason for limited testing should be stated if no or limited stimulation is performed.
- (3) Detection and reporting of VT recurrences.**
- (A) Recurrences for patients with an ICD.**
1. ICD interrogation should be obtained, whenever symptoms suggest an ICD therapy or at intervals sufficiently frequent to avoid ICD storage overload, and in the event of death.
 2. Because ICD data storage can be limited, recurrences should be categorized as follows
 - (a) VT/VF episodes with all diagnostic information, including EGMs
 - (b) VT/VF episodes with diagnostic information, but without EGMs.
 - (c) VT/VF episodes with unspecific diagnostic information
- (B) Recurrences for patients without ICDs**
1. Assessment for symptomatic VT recurrences requires ECG documentation (12-lead ECG or ambulatory monitor recordings)
 2. A search for asymptomatic slow VT at 6 months intervals using one of the following
 - (a) Trans-telephonic monitoring for 4 weeks around the follow-up interval, including symptom-triggered recording with a minimum of weekly transmissions to detect asymptomatic events.
 - (b) 24–72 h Holter monitoring.
 - (c) Thirty-day auto-triggered event monitoring or ambulatory telemetry.
-

methods, which does not provide an assessment of a change in frequency of VT that may be clinically relevant.

To address these problems, this Task Force proposes minimum reporting standards for conveying the results of catheter ablation for VT (Table 3). Several of these recommendations require elaboration.

Although it is recognized that the endpoints of a particular study have to be developed according to the design and purpose of the study, consistent monitoring techniques should be employed. It is critical that an indication of compliance with monitoring requirements be reported in published studies. The Task Force acknowledges that monitoring tools are a work in

Table 3 Continued

-
- (4) Follow-up and efficacy endpoints
- (A) A minimum follow-up duration of 6–12 months is required for an assessment of recurrent VT.
 - (B) A minimum follow-up duration of 1 year is required for assessment of mortality.
 - (C) VT recurrence is defined as any episode of VT of at least 30 s duration or that requires ICD intervention.
 - (D) Reporting of the following measures of efficacy is required
 1. Spontaneous recurrence of any sustained VT
 2. Freedom from VT in the absence of antiarrhythmic drug therapy.
–for this endpoint the follow-up period should begin five half lives after the drug has been stopped or at least 3 months after stopping amiodarone.
 3. Death
 - (E) Other outcomes that should be reported if possible
 1. Number of VT recurrences during the follow-up period
 2. Recurrence of monomorphic VT as opposed to ventricular fibrillation or polymorphic VT
 3. Freedom from VT with previously ineffective antiarrhythmic therapy.
 4. Improvement in VT frequency. A >75% decrease in the frequency of VT for a 6-month monitoring period before and after ablation is a reasonable measure of favourable clinical impact that has been used in previous multicenter trials.^{105,160}
 5. Quality of life as measured by accepted standardized tools
 6. Cost-effectiveness
- (5) Complications
- (A) All studies should include a complete reporting of major complications.
 - (B) Major complications are defined as those resulting in permanent injury or death, or that require intervention for treatment, or that prolong or require hospitalization.
-

progress and may not be uniformly available or practical for all patients. The suggested monitoring techniques represent a target standard for evaluating procedural efficacy:

The Task Force believes that reporting all categories of outcomes allows the readers to determine the relevant outcome for themselves and may provide important insights into the role of VT ablation in the management of patients with VT/VF. However, the gold standard for assessing the efficacy of new techniques and technology should remain freedom from VT/VF of >30 s duration in the absence of all antiarrhythmic drugs (excluding β -blocking agents).

Although Kaplan–Meier analyses are commonly used to report outcomes of VT ablation, particularly in randomized clinical trials, this methodology may underestimate the true effectiveness of VT ablation. This underestimation results from the fact that isolated recurrences of VT following catheter ablation are commonly observed. The members of this task force accept the notion that patients with these types of sporadic recurrences may achieve excellent long-term control and clinical benefit, despite rare recurrences. Because this pattern of benefit will be obscured by a Kaplan–Meier analysis, it is recommended that other alternative and/or secondary endpoints be reported in clinical trials. We therefore propose that clinical trials also report VT/VF at various points following ablation. It is essential that the method used for monitoring in the treatment and control arms be reported as part of this type of analysis.

Well-designed clinical trials will continue to provide a solid evidence base upon which to formulate practice guidelines in the future. The above reporting standards will lead to sufficient comparability to facilitate that goal.

A comment regarding the funding of clinical trials is consistent with the overarching goals of this VT Ablation Con-

sensus document. Although the value of programmes ensuring funding of basic investigation in cardiac electrophysiology is central to understanding arrhythmogenesis, funding of translational and clinical studies provides the critical means of extending and applying that information to patient care. Industry, third party payers, and government agencies should be strongly encouraged to provide the financial support needed to conduct these trials. The academic community should solidly support the paradigm of partnerships between these groups and private foundations, and clinicians should extend their patient advocacy to the level of these agencies and organizations to lobby for the necessary support for funding meritorious trials. More than passive support is required, active intervention from the basic laboratory to the clinic and from industry to insurance companies is needed.

X. Conclusions

Catheter ablation of VTs is increasingly performed. This document provides an up-to-date review of the indications, techniques, and outcomes. This statement summarizes the opinion of the task force members based on their analysis of the literature, as well as on their own experience in treating patients, and is directed to all healthcare professionals, healthcare institutions, manufacturers, and governmental, reimbursement, and regulatory bodies who are involved in the care of patients with VTs. Areas for which a consensus can be reached concerning VT ablation are identified. Nevertheless, it is important to note that when we use the term ‘consensus’ in this document, this indicates that >70% of the members were in agreement, and complete agreement was not always present. It is important to recognize that the selection of catheter ablation for the treatment of an individual patient must be made by the physician and patient with consideration of all the particular

co-morbidities and circumstances relevant to that patient. This document summarizes information to assist healthcare providers in caring for patients with VT. Finally, it is recognized that this field continues to evolve and that this document will need to be updated.

Uncited References

This section comprises of references that occur in the reference list but not in the body of the text. Please position each reference in the text or, alternatively, delete it. Any reference not dealt with will be retained in this section.³⁵²⁻³⁵⁴

Appendix

The task force writing group would like to thank members from EHRA, a Registered Branch of the ESC, HRS, ESC, AHA, and ACC for their thoughtful reviews of the document. Our thanks go to: Prof Martin Borggreffe, Prof. Antonio Ber-ruezo, Prof. Christian de Chillou, Dr Shih-Ann Chen, Dr L. Brent Mitchell, Dr N.A. Mark Estes III, Dr Alfred Buxton, Dr Usha Tedrow, Dr Claudio Schuger, Dr Paul Wang, Dr Andrea Russo, Dr Jennifer Cummings, Dr Wendy Gross, and Dr Jane Chen. All comments received were considered. Thank you for performing this valuable service.

Author relationships with industry

Author	Consulting fees/ honoraria	Speaker's Bureau	Ownership/ partnership/ principal	Research grants	Fellowship support and other benefit
Dr Etienne Aliot	Biotronik Cardiome Meda Pharma Medtronic Sanofi Aventis Sorin	None	None	None	None
Dr Jesus Ma Almendral Garrote	Boston Scientific St Jude Medical	None	None	None	None
Dr Frank Bogun Dr Hugh Calkins	None Biosense Webster* Boston Scientific Medtronic St Jude Medical	None None None	None None None	Biosense Webster Biosense Webster*	None Boston Scientific Medtronic
Dr Etienne Delacretaz Dr Paolo Della Bella	None Biosense Webster St Jude Medical*	None None	None None	None None	None None
Dr Gerhard Hindricks	Biosense Webster Biotronik* Cyberheart Medtronic St Jude Medical* Stereotaxis	None	None	None	None
Dr Pierre Jaïs	Biosense Webster Boston Scientific Sorin St Jude Medical Voyage Medical	None	None	Philips*	None
Dr Mark E. Josephson Dr Josef Kautzner	Medtronic Biosense Webster Biotroni Boston Scientific Hansen Medical St Jude Medical	None None	None None	None None	None None
Dr G. Neal Kay	Biosense Webster* Boston Scientific*	None	None	None	Biosense Webster* Boston Scientific* Medtronic* St Jude Medical*
Dr Karl-Heinz Kuck	St Jude Medical Stereotaxis	None	None	Biosense Webster	None

*Significant: a relationship is considered to be 'significant' if (1) the person receives \$10 000 or more during any 12-month period or 5% or more of the person's gross income or (2) the person owns 5% or more of the voting stock or share of the entity or owns \$10 000 or more of the fair market value of the entity. If the amount is under the preceding definition it is considered 'modest'.

Author	Consulting fees/ honoraria	Speaker's Bureau	Ownership/ partnership/ principal	Research grants	Fellowship support and other benefit
Dr Bruce Lerman	None	None	None	Boston Scientific* Medtronic* St Jude Medical* Biosense Webster*	Boston Scientific* Medtronic* St Jude Medical* Biosense Webster* Biotronik*
Dr Francis Marchlinski	Biosense Webster* Boston Scientific/ Guidant* GE Healthcare Medtronic* St Jude Medical*	None	None	St Jude Medical*	Boston Scientific/ Guidant* Medtronic* St Jude Medical*
Dr Vivek Reddy	Biosense Webster*	None	None	Biosense Webster* St Jude Medical*	None
Dr Martin-Jan Schalij	St Jude Medical* Boston Scientific	Biotronik Boston Scientific	None	Biotronik* Boston Scientific* Medtronic* St Jude Medical*	None
Dr Richard Schilling	None	Biosense Webster St Jude Medical	None	None	Boston Scientific* Medtronic*
Dr Kyoko Soejima	Medtronic Japan Toray Japan	None	None	None	None
Dr William Gregory Stevenson	Biosense Webster Boston Scientific Medtronic St Jude Medical	None	None	None	None
Dr David Wilber	Biosense Webster Boston Scientific Cardio Insight Medtronic St Jude Medical Stereotaxis	None	None	None	None

*Significant: a relationship is considered to be 'significant' if (1) the person receives \$10 000 or more during any 12-month period or 5% or more of the person's gross income or (2) the person owns 5% or more of the voting stock or share of the entity or owns \$10 000 or more of the fair market value of the entity. If the amount is under the preceding definition it is considered 'modest'.

References

- Lerman BB. Mechanism of outflow tract tachycardia. *Heart Rhythm* 2007;4: 973–6.
- Tada H, Ito S, Naito S, Kurosaki K, Kubota S, Sugiyasu A et al. Idiopathic ventricular arrhythmia arising from the mitral annulus: a distinct subgroup of idiopathic ventricular arrhythmias. *J Am Coll Cardiol* 2005;45:877–86.
- Tada H, Tadokoro K, Ito S, Naito S, Hashimoto T, Kaseno K et al. Idiopathic ventricular arrhythmias originating from the tricuspid annulus: prevalence, electrocardiographic characteristics, and results of radiofrequency catheter ablation. *Heart Rhythm* 2007;4:7–16.
- Tanner H, Hindricks G, Schirdewahn P, Kobza R, Dorszewski A, Piorkowski C et al. Outflow tract tachycardia with R/S transition in lead V3: six different anatomic approaches for successful ablation. *J Am Coll Cardiol* 2005;45:418–23.
- Buxton AE, Waxman HL, Marchlinski FE, Simson MB, Cassidy D, Josephson ME. Right ventricular tachycardia: clinical and electrophysiologic characteristics. *Circulation* 1983;68:917–27.
- Ito S, Tada H, Naito S, Kurosaki K, Ueda M, Hoshizaki H et al. Development and validation of an ECG algorithm for identifying the optimal ablation site for idiopathic ventricular outflow tract tachycardia. *J Cardiovasc Electrophysiol* 2003;14:1280–6.
- Kamakura S, Shimizu W, Matsuo K, Taguchi A, Suyama K, Kurita T et al. Localization of optimal ablation site of idiopathic ventricular tachycardia from right and left ventricular outflow tract by body surface ECG. *Circulation* 1998; 98:1525–33.
- Lerman BB, Belardinelli L, West GA, Berne RM, DiMarco JP. Adenosine-sensitive ventricular tachycardia: evidence suggesting cyclic AMP-mediated triggered activity. *Circulation* 1986;74:270–80.
- Lerman BB, Stein K, Engelstein ED, Battleman DS, Lippman N, Bei D et al. Mechanism of repetitive monomorphic ventricular tachycardia. *Circulation* 1995;92:421–9.
- Morady F, Kadish AH, DiCarlo L, Kou WH, Winston S, deBuitier M et al. Long-term results of catheter ablation of idiopathic right ventricular tachycardia. *Circulation* 1990;82:2093–9.
- Sung RJ, Keung EC, Nguyen NX, Huycke EC. Effects of beta-adrenergic blockade on verapamil-responsive and verapamil-irresponsive sustained ventricular tachycardias. *J Clin Invest* 1988;81:688–99.
- Tada H, Tadokoro K, Miyaji K, Ito S, Kurosaki K, Kaseno K et al. Idiopathic ventricular arrhythmias arising from the pulmonary artery: prevalence, characteristics, and topography of the arrhythmia origin. *Heart Rhythm* 2008;5:419–26.
- Antzelevitch C, Shimizu W. Cellular mechanisms underlying the long QT syndrome. *Curr Opin Cardiol* 2002;17:43–51.
- Haissaguerre M, Extramiana F, Hocini M, Cauchemez B, Jais P, Cabrera JA et al. Mapping and ablation of ventricular fibrillation associated with long-QT and Brugada syndromes. *Circulation* 2003;108:925–8.
- Lerman BB. Response of nonreentrant catecholamine-mediated ventricular tachycardia to endogenous adenosine and acetylcholine. Evidence for myocardial receptor-mediated effects. *Circulation* 1993;87:382–90.
- Damle RS, Landers M, Kelly PA, Reiter MJ, Mann DE. Radiofrequency catheter ablation of idiopathic left ventricular tachycardia originating in the left anterior fascicle. *Pacing Clin Electrophysiol* 1998;21:1155–8.
- Lopera G, Stevenson WG, Soejima K, Maisel WH, Koplan B, Sapp JL et al. Identification and ablation of three types of ventricular tachycardia involving the His-Purkinje system in patients with heart disease. *J Cardiovasc Electrophysiol* 2004; 15:52–8.

18. Huelsing DJ, Spitzer KW, Pollard AE. Spontaneous activity induced in rabbit Purkinje myocytes during coupling to a depolarized model cell. *Cardiovasc Res* 2003; 59:620-7.
19. Spitzer KW, Pollard AE, Yang L, Zaniboni M, Cordeiro JM, Huelsing DJ. Cell-to-cell electrical interactions during early and late repolarization. *J Cardiovasc Electrophysiol* 2006;17(Suppl. 1):S8-14.
20. Belhassen B, Caspi A, Miller H, Shapira I, Laniado S. Extensive endocardial mapping during sinus rhythm and ventricular tachycardia in a patient with arrhythmogenic right ventricular dysplasia. *J Am Coll Cardiol* 1984;4:1302-6.
21. Delacretaz E, Stevenson WG, Ellison KE, Maisel WH, Friedman PL. Mapping and radiofrequency catheter ablation of the three types of sustained monomorphic ventricular tachycardia in nonischemic heart disease. *J Cardiovasc Electrophysiol* 2000;11:11-17.
22. Eckart RE, Hruczkowski TW, Tedrow UB, Koplan BA, Epstein LM, Stevenson WG. Sustained ventricular tachycardia associated with corrective valve surgery. *Circulation* 2007;116:2005-11.
23. Ellison KE, Friedman PL, Ganz LI, Stevenson WG. Entrainment mapping and radiofrequency catheter ablation of ventricular tachycardia in right ventricular dysplasia. *J Am Coll Cardiol* 1998;32:724-8.
24. Hsia HH, Marchlinski FE. Electrophysiology studies in patients with dilated cardiomyopathies. *Card Electrophysiol Rev* 2002;6:472-81.
25. Josephson ME, Horowitz LN, Farshidi A, Kastor JA. Recurrent sustained ventricular tachycardia. I. Mechanisms. *Circulation* 1978;57:431-40.
26. Josephson ME, Almendral JM, Buxton AE, Marchlinski FE. Mechanisms of ventricular tachycardia. *Circulation* 1987;75(Pt 2):III41-7.
27. Koplan BA, Soejima K, Baughman K, Epstein LM, Stevenson WG. Refractory ventricular tachycardia secondary to cardiac sarcoid: electrophysiologic characteristics, mapping, and ablation. *Heart Rhythm* 2006;3:924-9.
28. Marchlinski FE, Zado E, Dixit S, Gerstenfeld E, Callans DJ, Hsia H et al. Electroanatomic substrate and outcome of catheter ablation therapy for ventricular tachycardia in setting of right ventricular cardiomyopathy. *Circulation* 2004;110:2293-8.
29. Sosa E, Scanavacca M, D'Avila A, Piccioni J, Sanchez O, Velarde JL et al. Endocardial and epicardial ablation guided by nonsurgical transthoracic epicardial mapping to treat recurrent ventricular tachycardia. *J Cardiovasc Electrophysiol* 1998;9:229-39.
30. Stevenson WG, Khan H, Sager P, Saxon LA, Middlekauff HR, Natterson PD et al. Identification of reentry circuit sites during catheter mapping and radiofrequency ablation of ventricular tachycardia late after myocardial infarction. *Circulation* 1993;88(Pt 1):1647-70.
31. Dillon SM, Alessie MA, Ursell PC, Wit AL. Influences of anisotropic tissue structure on reentrant circuits in the epicardial border zone of subacute canine infarcts. *Circ Res* 1988;63:182-206.
32. Downar E, Harris L, Mickleborough LL, Shaikh N, Parson ID. Endocardial mapping of ventricular tachycardia in the intact human ventricle: evidence for reentrant mechanisms. *J Am Coll Cardiol* 1988;11:783-91.
33. Downar E, Kimber S, Harris L, Mickleborough L, Sevaptisid E, Masse S et al. Endocardial mapping of ventricular tachycardia in the intact human heart. II. Evidence for multiuse reentry in a functional sheet of surviving myocardium. *J Am Coll Cardiol* 1992;20:869-78.
34. Kleber AG, Rudy Y. Basic mechanisms of cardiac impulse propagation and associated arrhythmias. *Physiol Rev* 2004;84:431-88.
35. de Bakker JM, van Capelle FJ, Janse MJ, Wilde AA, Coronel R, Becker AE et al. Reentry as a cause of ventricular tachycardia in patients with chronic ischemic heart disease: electrophysiologic and anatomic correlation. *Circulation* 1988;77:589-606.
36. Downar E, Harris L, Kimber S, Mickleborough L, Williams W, Sevaptisid E et al. Ventricular tachycardia after surgical repair of tetralogy of Fallot: results of intraoperative mapping studies. *J Am Coll Cardiol* 1992;20:648-55.
37. El-Sherif N, Smith RA, Evans K. Canine ventricular arrhythmias in the late myocardial infarction period. 8. Epicardial mapping of reentrant circuits. *Circ Res* 1981;49:255-65.
38. El-Sherif N, Mehra R, Gough WB, Zeiler RH. Reentrant ventricular arrhythmias in the late myocardial infarction period. Interruption of reentrant circuits by cryothermal techniques. *Circulation* 1983;68:644-56.
39. Horowitz LN, Vetter VL, Harken AH, Josephson ME. Electrophysiologic characteristics of sustained ventricular tachycardia occurring after repair of tetralogy of fallot. *Am J Cardiol* 1980;46:446-52.
40. Kugler JD, Pinsky WW, Cheatham JP, Hofschire PJ, Mooring PK, Fleming WH. Sustained ventricular tachycardia after repair of tetralogy of Fallot: new electrophysiologic findings. *Am J Cardiol* 1983;51:1137-43.
41. Ouyang F, Fotuhi P, Ho SY, Hebe J, Volkmer M, Goya M et al. Repetitive monomorphic ventricular tachycardia originating from the aortic sinus cusp: electrocardiographic characterization for guiding catheter ablation. *J Am Coll Cardiol* 2002;39:500-8.
42. Baba S, Dun W, Cabo C, Boyden PA. Remodeling in cells from different regions of the reentrant circuit during ventricular tachycardia. *Circulation* 2005;112:2386-96.
43. Peters NS, Wit AL. Myocardial architecture and ventricular arrhythmogenesis. *Circulation* 1998;97:1746-54.
44. de Bakker JM, Coronel R, Tasseron S, Wilde AA, Ophof T, Janse MJ et al. Ventricular tachycardia in the infarcted, Langendorff-perfused human heart: role of the arrangement of surviving cardiac fibers. *J Am Coll Cardiol* 1990;15:1594-607.
45. de Bakker JM, van Capelle FJ, Janse MJ, Tasseron S, Vermeulen JT, de JN et al. Slow conduction in the infarcted human heart. 'Zigzag' course of activation. *Circulation* 1993;88:915-26.
46. Kawara T, Derksen R, de Groot JR, Coronel R, Tasseron S, Linnenbank AC et al. Activation delay after premature stimulation in chronically diseased human myocardium relates to the architecture of interstitial fibrosis. *Circulation* 2001;104:3069-75.
47. de Bakker JM, Stein M, van Rijen HV. Three-dimensional anatomic structure as substrate for ventricular tachycardia/ventricular fibrillation. *Heart Rhythm* 2005;2:777-9.
48. Josephson ME, Harken AH, Horowitz LN. Endocardial excision: a new surgical technique for the treatment of recurrent ventricular tachycardia. *Circulation* 1979;60:1430-9.
49. Klein GJ, Ideker RE, Smith WM, Harrison LA, Kasell J, Wallace AG et al. Epicardial mapping of the onset of ventricular tachycardia initiated by programmed stimulation in the canine heart with chronic infarction. *Circulation* 1979;60:1375-84.
50. Bogun F, Good E, Reich S, Elmouchi D, Igic P, Lemola K et al. Isolated potentials during sinus rhythm and pace-mapping within scars as guides for ablation of post-infarction ventricular tachycardia. *J Am Coll Cardiol* 2006;47:2013-9.
51. Bruckhorst CB, Delacretaz E, Soejima K, Maisel WH, Friedman PL, Stevenson WG. Identification of the ventricular tachycardia isthmus after infarction by pace mapping. *Circulation* 2004;110:652-9.
52. Miller JM, Tyson GS, Hargrove WC III, Vassallo JA, Rosenthal ME, Josephson ME. Effect of subendocardial resection on sinus rhythm endocardial electrogram abnormalities. *Circulation* 1995;91:2385-91.
53. Soejima K, Stevenson WG, Maisel WH, Sapp JL, Epstein LM. Electrically unexcitable scar mapping based on pacing threshold for identification of the reentry circuit isthmus: feasibility for guiding ventricular tachycardia ablation. *Circulation* 2002;106:1678-83.
54. de Chillou C, Lacroix D, Klug D, Magnin-Poull I, Marquie C, Messier M et al. Isthmus characteristics of reentrant ventricular tachycardia after myocardial infarction. *Circulation* 2002;105:726-31.
55. Hsia HH, Lin D, Sauer WH, Callans DJ, Marchlinski FE. Anatomic characterization of endocardial substrate for hemodynamically stable reentrant ventricular tachycardia: identification of endocardial conducting channels. *Heart Rhythm* 2006;3:503-12.
56. Littmann L, Svenson RH, Gallagher JJ, Selle JG, Zimmern SH, Fedor JM et al. Functional role of the epicardium in postinfarction ventricular tachycardia. Observations derived from computerized epicardial activation mapping, entrainment, and epicardial laser photoablation. *Circulation* 1991;83:1577-91.
57. Wilber DJ, Kopp DE, Glascock DN, Kinder CA, Kall JG. Catheter ablation of the mitral isthmus for ventricular tachycardia associated with inferior infarction. *Circulation* 1995;92:3481-89.
58. Pogwizd SM, Hoyt RH, Saffitz JE, Corr PB, Cox JL, Cain ME. Reentrant and focal mechanisms underlying ventricular tachycardia in the human heart. *Circulation* 1992;86:1872-87.
59. Soejima K, Suzuki M, Maisel WH, Bruckhorst CB, Delacretaz E, Blier L et al. Catheter ablation in patients with multiple and unstable ventricular tachycardias after myocardial infarction: short ablation lines guided by reentry circuit isthmuses and sinus rhythm mapping. *Circulation* 2001;104:664-9.
60. El-Sherif N, Gough WB, Zeiler RH, Hariman R. Reentrant ventricular arrhythmias in the late myocardial infarction period. 12. Spontaneous versus induced reentry and intramural versus epicardial circuits. *J Am Coll Cardiol* 1985;6:124-32.
61. Marchlinski FE. Perivalvular fibrosis and monomorphic ventricular tachycardia: toward a unifying hypothesis in nonischemic cardiomyopathy. *Circulation* 2007;116:1998-2001.
62. Klemm HU, Ventura R, Steven D, Johnsen C, Rostock T, Lutomsy B et al. Catheter ablation of multiple ventricular tachycardias after myocardial infarction guided by combined contact and noncontact mapping. *Circulation* 2007;115:2697-704.
63. Brugada P, Abdollah H, Wellens HJ. Continuous electrical activity during sustained monomorphic ventricular tachycardia. Observations on its dynamic behavior during the arrhythmia. *Am J Cardiol* 1985;55:402-11.

64. Lin JW, Garber L, Qi YR, Chang MG, Cysyk J, Tung L. Region [corrected] of slowed conduction acts as core for spiral wave reentry in cardiac cell monolayers. *Am J Physiol Heart Circ Physiol* 2008;294:H58–65.
65. Caceres J, Jazayeri M, McKinnie J, Avitall B, Denker ST, Tchou P et al. Sustained bundle branch reentry as a mechanism of clinical tachycardia. *Circulation* 1989;79:256–70.
66. Hadjis TA, Stevenson WG, Harada T, Friedman PL, Sager P, Saxon LA. Preferential locations for critical reentry circuit sites causing ventricular tachycardia after inferior wall myocardial infarction. *J Cardiovasc Electrophysiol* 1997;8:363–70.
67. Crijns HJ, Smeets JL, Rodriguez LM, Meijer A, Wellens HJ. Cure of inter fascicular reentrant ventricular tachycardia by ablation of the anterior fascicle of the left bundle branch. *J Cardiovasc Electrophysiol* 1995;6:486–92.
68. Tchou P, Jazayeri M, Denker S, Dongas J, Caceres J, Akhtar M. Transcatheter electrical ablation of right bundle branch. A method of treating macroreentrant ventricular tachycardia attributed to bundle branch reentry. *Circulation* 1988;78:246–57.
69. Nakagawa H, Beckman KJ, McClelland JH, Wang X, Arruda M, Santoro I et al. Radiofrequency catheter ablation of idiopathic left ventricular tachycardia guided by a Purkinje potential. *Circulation* 1993;88:2607–17.
70. Rodriguez LM, Smeets JL, Timmermans C, Trappe HJ, Wellens HJ. Radiofrequency catheter ablation of idiopathic ventricular tachycardia originating in the anterior fascicle of the left bundle branch. *J Cardiovasc Electrophysiol* 1996;7:1211–6.
71. Kaltenbrunner W, Cardinal R, Dubuc M, Shenasa M, Nadeau R et al. Epicardial and endocardial mapping of ventricular tachycardia in patients with myocardial infarction. Is the origin of the tachycardia always subendocardially localized? *Circulation* 1991;84:1058–71.
72. Stevenson WG, Friedman PL, Kocovic D, Sager PT, Saxon LA, Pavri B. Radiofrequency catheter ablation of ventricular tachycardia after myocardial infarction. *Circulation* 1998;98:308–14.
73. Marchlinski FE, Callans DJ, Gottlieb CD, Zado E. Linear ablation lesions for control of unmappable ventricular tachycardia in patients with ischemic and nonischemic cardiomyopathy. *Circulation* 2000;101:1288–96.
74. Ouyang F, Antz M, Deger FT, Bansch D, Schaumann A, Ernst S et al. An underrecognized subepicardial reentrant ventricular tachycardia attributable to left ventricular aneurysm in patients with normal coronary arteriograms. *Circulation* 2003;107:2702–9.
75. Sosa E, Scanavacca M, D'Avila A, Bellotti G, Pilleggi F. Radiofrequency catheter ablation of ventricular tachycardia guided by nonsurgical epicardial mapping in chronic Chagas heart disease. *Pacing Clin Electrophysiol* 1999;22(Pt 1):128–30.
76. Irvine J, Dorian P, Baker B, O'Brien BJ, Roberts R, Gent M et al. Quality of life in the Canadian Implantable Defibrillator Study (CIDS). *Am Heart J* 2002;144:282–9.
77. Mark DB, Anstrom KJ, Sun JL, Clapp-Channing NE, Tsiatis AA, vidson-Ray L et al. Quality of life with defibrillator therapy or amiodarone in heart failure. *N Engl J Med* 2008;359:999–1008.
78. Moss AJ, Greenberg H, Case RB, Zareba W, Hall WJ, Brown MW et al. Long-term clinical course of patients after termination of ventricular tachyarrhythmia by an implanted defibrillator. *Circulation* 2004;110:3760–5.
79. Poole JE, Johnson GW, Hellkamp AS, Anderson J, Callans DJ, Raitt MH et al. Prognostic importance of defibrillator shocks in patients with heart failure. *N Engl J Med* 2008;359:1009–17.
80. Schron EB, Exner DV, Yao Q, Jenkins LS, Steinberg JS, Cook JR et al. Quality of life in the antiarrhythmics versus implantable defibrillators trial: impact of therapy and influence of adverse symptoms and defibrillator shocks. *Circulation* 2002;105:589–94.
81. Bollmann A, Husser D, Cannom DS. Antiarrhythmic drugs in patients with implantable cardioverter-defibrillators. *Am J Cardiovasc Drugs* 2005;5:371–8.
82. Connolly SJ, Dorian P, Roberts RS, Gent M, Bailin S, Fain ES, Thorp K et al. Comparison of beta-blockers, amiodarone plus beta-blockers, or sotalol for prevention of shocks from implantable cardioverter defibrillators: the OPTIC study: a randomized trial. *J Am Med Assoc* 2006;295:165–71.
83. Pacifico A, Hohnloser SH, Williams JH, Tao B, Saksena S, Henry PD et al. Prevention of implantable-defibrillator shocks by treatment with sotalol. d.I-Sotalol Implantable Cardioverter-Defibrillator Study Group. *N Engl J Med* 1999;340:1855–62.
84. Gepstein L, Hayam G, Ben-Haim SA. A novel method for nonfluoroscopic catheter-based electroanatomical mapping of the heart. In vitro and in vivo accuracy results. *Circulation* 1997;95:1611–22.
85. Dixit S, Narula N, Callans DJ, Marchlinski FE. Electroanatomic mapping of human heart: epicardial fat can mimic scar. *J Cardiovasc Electrophysiol* 2003;14:1128.
86. Soejima K, Stevenson WG, Sapp JL, Selwyn AP, Couper G, Epstein LM. Endocardial and epicardial radiofrequency ablation of ventricular tachycardia associated with dilated cardiomyopathy: the importance of low-voltage scars. *J Am Coll Cardiol* 2004;43:1834–42.
87. Swarup V, Morton JB, Arruda M, Wilber DJ. Ablation of epicardial macroreentrant ventricular tachycardia associated with idiopathic nonischemic dilated cardiomyopathy by a percutaneous transthoracic approach. *J Cardiovasc Electrophysiol* 2002;13:1164–8.
88. Roux JF, Dubuc M, Pressacco J, Roy D, Thibault B, Talajic M et al. Concordance between an electroanatomic mapping system and cardiac MRI in arrhythmogenic right ventricular cardiomyopathy. *Pacing Clin Electrophysiol* 2006;29:109–12.
89. Wittkampf FH, Wever EF, Derksen R, Wilde AA, Ramanna H, Hauer RN et al. Localisa: new technique for real-time 3-dimensional localization of regular intracardiac electrodes. *Circulation* 1999;99:1312–7.
90. Khaykin Y, Skanes A, Whaley B, Hill C, Beardsall M, Seabrook C et al. Real-time integration of 2D intracardiac echocardiography and 3D electroanatomical mapping to guide ventricular tachycardia ablation. *Heart Rhythm* 2008;5:1396–1402.
91. Khongphathanayothin A, Kosar E, Nademanee K. Nonfluoroscopic three-dimensional mapping for arrhythmia ablation: tool or toy? *J Cardiovasc Electrophysiol* 2000;11:239–43.
92. Nademanee K, Kosar EM. A nonfluoroscopic catheter-based mapping technique to ablate focal ventricular tachycardia. *Pacing Clin Electrophysiol* 1998;21:1442–7.
93. Ouyang F, Cappato R, Ernst S, Goya M, Volkmer M, Hebe J et al. Electroanatomic substrate of idiopathic left ventricular tachycardia: unidirectional block and macroreentry within the purkinje network. *Circulation* 2002;105:462–9.
94. Varanasi S, Dhala A, Blanck Z, Deshpande S, Akhtar M, Sra J. Electroanatomic mapping for radiofrequency ablation of cardiac arrhythmias. *J Cardiovasc Electrophysiol* 1999;10:538–44.
95. Arenal A, Glez-Torrecilla E, Ortiz M, Villacastin J, Fdez-Portales J, Sousa E et al. Ablation of electrograms with an isolated, delayed component as treatment of unmappable monomorphic ventricular tachycardias in patients with structural heart disease. *J Am Coll Cardiol* 2003;41:81–92.
96. Brunckhorst CB, Delacretaz E, Soejima K, Jackman WM, Nakagawa H, Kuck KH et al. Ventricular mapping during atrial and right ventricular pacing: relation of electrogram parameters to ventricular tachycardia reentry circuits after myocardial infarction. *J Interv Card Electrophysiol* 2004;11:183–91.
97. Codreanu A, Odille F, Aliot E, Marie PY, Magnin-Poull I, Andronache M et al. Electroanatomic characterization of post-infarct scars comparison with 3-dimensional myocardial scar reconstruction based on magnetic resonance imaging. *J Am Coll Cardiol* 2008;52:839–42.
98. Kautzner J, Cihak R, Peichl P, Vancura V, Bytesnik J. Catheter ablation of ventricular tachycardia following myocardial infarction using three-dimensional electroanatomical mapping. *Pacing Clin Electrophysiol* 2003;26(Pt 2):342–7.
99. Kottkamp H, Wetzel U, Schirdewahn P, Dorszewski A, Gerdts-Li JH, Carbucicchio C et al. Catheter ablation of ventricular tachycardia in remote myocardial infarction: substrate description guiding placement of individual linear lesions targeting noninducibility. *J Cardiovasc Electrophysiol* 2003;14:675–81.
100. Miljoen H, State S, de Chillou C, Magnin-Poull I, Dotto P, Andronache M et al. Electroanatomic mapping characteristics of ventricular tachycardia in patients with arrhythmogenic right ventricular cardiomyopathy/dysplasia. *Europace* 2005;7:516–24.
101. Reddy VY, Neuzil P, Taborsky M, Ruskin JN. Short-term results of substrate mapping and radiofrequency ablation of ischemic ventricular tachycardia using a saline-irrigated catheter. *J Am Coll Cardiol* 2003;41:2228–36.
102. Reddy VY, Reynolds MR, Neuzil P, Richardson AW, Taborsky M, Jongnarangsin K et al. Prophylactic catheter ablation for the prevention of defibrillator therapy. *N Engl J Med* 2007;357:2657–65.
103. Reithmann C, Hahnefeld A, Remp T, Dorwarth U, Dugas M, Steinbeck G et al. Electroanatomic mapping of endocardial right ventricular activation as a guide for catheter ablation in patients with arrhythmogenic right ventricular dysplasia. *Pacing Clin Electrophysiol* 2003;26:1308–16.
104. Stevenson WG, Delacretaz E, Friedman PL, Ellison KE. Identification and ablation of macroreentrant ventricular tachycardia with the CARTO electroanatomical mapping system. *Pacing Clin Electrophysiol* 1998;21:1448–56.
105. Stevenson WG, Wilber DJ, Natale A, Jackman WM, Marchlinski FE, Talbert T et al. Irrigated radiofrequency catheter ablation guided by electroanatomic mapping for recurrent ventricular tachycardia after myocardial infarction: the multicenter thermocool ventricular tachycardia ablation trial. *Circulation* 2008;118:2773–82.
106. Tanner H, Hindricks G, Volkmer M, Furniss S, kuhlkamp V, Lacroix D et al. Catheter ablation of recurrent scar-related ventricular tachycardia using electroanatomical mapping and irrigated ablation technology: Results of the prospective multicenter Euro-VT-Study. 2009 (in press).

107. Tomassoni G, Stanton M, Richey M, Leonelli FM, Beheiry S, Natale A. Epicardial mapping and radiofrequency catheter ablation of ischemic ventricular tachycardia using a three-dimensional nonfluoroscopic mapping system. *J Cardiovasc Electrophysiol* 1999;10:1643-8.
108. Chauhan VS, Nair GM, Sevaptisidis E, Downar E. Magneto-electroanatomic mapping of arrhythmias in structural heart disease using a novel multielectrode catheter. *Pacing Clin Electrophysiol* 2004;27:1077-84.
109. Patel AM, D'Avila A, Neuzil P, Kim SJ, Mela T, Singh J et al. Atrial tachycardia after ablation of persistent atrial fibrillation: identification of the critical isthmus with a combination of multielectrode activation mapping and targeted entrainment mapping. *Circ Arrhythmia Electrophysiol* 2008;1:14-22.
110. Greenspon AJ, Hsu SS, Datorre S. Successful radiofrequency catheter ablation of sustained ventricular tachycardia postmyocardial infarction in man guided by a multielectrode "basket" catheter. *J Cardiovasc Electrophysiol* 1997;8:565-70.
111. Schaliq MJ, van Ruge FP, Siezenga M, van der Velde ET. Endocardial activation mapping of ventricular tachycardia in patients: first application of a 32-site bipolar mapping electrode catheter. *Circulation* 1998;98:2168-79.
112. Yoshida Y, Hirai M, Murakami Y, Kondo T, Inden Y, Akahoshi M et al. Localization of precise origin of idiopathic ventricular tachycardia from the right ventricular outflow tract by a 12-lead ECG: a study of pace mapping using a multielectrode "basket" catheter. *Pacing Clin Electrophysiol* 1999;22:1760-8.
113. Thornton AS, Jordaens LJ. Remote magnetic navigation for mapping and ablating right ventricular outflow tract tachycardia. *Heart Rhythm* 2006;3:691-6.
114. Gornick CC, Adler SW, Pederson B, Hauck J, Budd J, Schweitzer J. Validation of a new noncontact catheter system for electroanatomic mapping of left ventricular endocardium. *Circulation* 1999;99:829-35.
115. Schilling RJ, Peters NS, Davies DW. Simultaneous endocardial mapping in the human left ventricle using a noncontact catheter: comparison of contact and reconstructed electrograms during sinus rhythm. *Circulation* 1998;98:887-98.
116. Schilling RJ, Peters NS, Davies DW. Feasibility of a noncontact catheter for endocardial mapping of human ventricular tachycardia. *Circulation* 1999;99:2543-52.
117. Sivagangabalan G, Poulipoulos J, Huang K, Lu J, Barry M, Thiagalingam A et al. Comparison of electroanatomic contact and noncontact mapping of ventricular scar in postinfarct ovine model with intramural needle electrode recording and histological validation. *Circ Arrhythmia Electrophysiol* 2008;1:363-9.
118. Della BP, Pappalardo A, Riva S, Tondo C, Fassini G, Trevisi N. Non-contact mapping to guide catheter ablation of intolerated ventricular tachycardia. *Eur Heart J* 2002;23:742-52.
119. Segal OR, Chow AW, Markides V, Schilling RJ, Peters NS, Davies DW. Long-term results after ablation of infarct-related ventricular tachycardia. *Heart Rhythm* 2005;2:474-82.
120. Abrams DJ, Earley MJ, Sporton SC, Kistler PM, Gatzoulis MA, Mullen MJ et al. Comparison of noncontact and electroanatomic mapping to identify scar and arrhythmia late after the Fontan procedure. *Circulation* 2007;115:1738-46.
121. Jacobson JT, Afonso VX, Eisenman G, Schultz JR, Lazar S, Michele JJ et al. Characterization of the infarct substrate and ventricular tachycardia circuits with non-contact unipolar mapping in a porcine model of myocardial infarction. *Heart Rhythm* 2006;3:189-97.
122. Voss F, Steen H, Bauer A, Giannitsis E, Katus HA, Becker R. Determination of myocardial infarct size by noncontact mapping. *Heart Rhythm* 2008;5:308-14.
123. Chen M, Yang B, Zou J, Shan Q, Chen C, Xu D et al. Non-contact mapping and linear ablation of the left posterior fascicle during sinus rhythm in the treatment of idiopathic left ventricular tachycardia. *Europace* 2005;7:138-44.
124. Friedman PA, Asirvatham SJ, Grice S, Glikson M, Munger TM, Rea RF et al. Non-contact mapping to guide ablation of right ventricular outflow tract tachycardia. *J Am Coll Cardiol* 2002;39:1808-12.
125. Ribbing M, Wasmer K, Monnig G, Kirchhof P, Loh P, Breithardt G et al. Endocardial mapping of right ventricular outflow tract tachycardia using non-contact activation mapping. *J Cardiovasc Electrophysiol* 2003;14:602-8.
126. Yao Y, Zhang S, He DS, Zhang K, Hua W, Chu J et al. Radiofrequency ablation of the ventricular tachycardia with arrhythmogenic right ventricular cardiomyopathy using non-contact mapping. *Pacing Clin Electrophysiol* 2007;30:526-33.
127. Kriebel T, Saul JP, Schneider H, Sigler M, Paul T. Noncontact mapping and radiofrequency catheter ablation of fast and hemodynamically unstable ventricular tachycardia after surgical repair of tetralogy of Fallot. *J Am Coll Cardiol* 2007; 50:2162-8.
128. Rajappan K, Schilling RJ. Non-contact mapping in the treatment of ventricular tachycardia after myocardial infarction. *J Interv Card Electrophysiol* 2007;19: 9-18.
129. Strickerberger SA, Knight BP, Michaud GF, Pelosi F, Morady F. Mapping and ablation of ventricular tachycardia guided by virtual electrograms using a noncontact, computerized mapping system. *J Am Coll Cardiol* 2000;35:414-21.
130. Al-Ahmad A, Grossman JD, Wang PJ. Early experience with a computerized robotically controlled catheter system. *J Interv Card Electrophysiol* 2005;12: 199-202.
131. Saliba W, Cummings JE, Oh S, Zhang Y, Mazgalev TN, Schweikert RA et al. Novel robotic catheter remote control system: feasibility and safety of transseptal puncture and endocardial catheter navigation. *J Cardiovasc Electrophysiol* 2006; 17:1102-5.
132. Faddis MN, Blume W, Finney J, Hall A, Rauch J, Sell J et al. Novel, magnetically guided catheter for endocardial mapping and radiofrequency catheter ablation. *Circulation* 2002;106:2980-5.
133. Greenberg S, Blume W, Faddis M, Finney J, Hall A, Talcott M et al. Remote controlled magnetically guided pulmonary vein isolation in canines. *Heart Rhythm* 2006;3:71-6.
134. Pappone C, Vicedomini G, Manguso F, Gugliotta F, Mazzone P, Gulletta S et al. Robotic magnetic navigation for atrial fibrillation ablation. *J Am Coll Cardiol* 2006; 47:1390-400.
135. Aryana A, D'Avila A, Heist EK, Mela T, Singh JP, Ruskin JN et al. Remote magnetic navigation to guide endocardial and epicardial catheter mapping of scar-related ventricular tachycardia. *Circulation* 2007;115:1191-200.
136. Burkhardt JD, Saliba WI, Schweikert RA, Cummings J, Natale A. Remote magnetic navigation to map and ablate left coronary cusp ventricular tachycardia. *J Cardiovasc Electrophysiol* 2006;17:1142-4.
137. Thornton AS, Res J, Mekel JM, Jordaens LJ. Use of advanced mapping and remote magnetic navigation to ablate left ventricular fascicular tachycardia. *Pacing Clin Electrophysiol* 2006;29:685-8.
138. Bogun F, Morady F. Ablation of ventricular tachycardia in patients with non-ischemic cardiomyopathy. *J Cardiovasc Electrophysiol* 2008;19:1227-30.
139. Nazarian S, Bluemke DA, Lardo AC, Zviman MM, Watkins SP, Dickfeld TL et al. Magnetic resonance assessment of the substrate for inducible ventricular tachycardia in nonischemic cardiomyopathy. *Circulation* 2005;112:2821-5.
140. Schmidt A, Azevedo CF, Cheng A, Gupta SN, Bluemke DA, Foo TK et al. Infarct tissue heterogeneity by magnetic resonance imaging identifies enhanced cardiac arrhythmia susceptibility in patients with left ventricular dysfunction. *Circulation* 2007;115:2006-14.
141. Faris OP, Shein M. Food and Drug Administration perspective: magnetic resonance imaging of pacemaker and implantable cardioverter-defibrillator patients. *Circulation* 2006;114:1232-3.
142. Nazarian S, Roguin A, Zviman MM, Lardo AC, Dickfeld TL, Calkins H et al. Clinical utility and safety of a protocol for noncardiac and cardiac magnetic resonance imaging of patients with permanent pacemakers and implantable-cardioverter defibrillators at 1.5 tesla. *Circulation* 2006;114:1277-84.
143. Roguin A, Schwitzer J, Vahlhaus C, Lombardi M, Brugada J, Vardas P et al. Magnetic resonance imaging in individuals with cardiovascular implantable electronic devices. *Europace* 2008;10:336-46.
144. Bello D, Kipper S, Valderrabano M, Shivkumar K. Catheter ablation of ventricular tachycardia guided by contrast-enhanced cardiac computed tomography. *Heart Rhythm* 2004;1:490-2.
145. Dickfeld T, Koehler C. The role of integrated PET-CT scar maps for guiding ventricular tachycardia ablations. *Curr Cardiol Rep* 2008;10:149-57.
146. Ashikaga H, Sasano T, Dong J, Zviman MM, Evers R, Hopenfeld B et al. Magnetic resonance-based anatomical analysis of scar-related ventricular tachycardia: implications for catheter ablation. *Circ Res* 2007;101:939-47.
147. Reddy VY, Malchano ZJ, Holmvang G, Schmidt EJ, D'Avila A, Houghtaling C et al. Integration of cardiac magnetic resonance imaging with three-dimensional electroanatomic mapping to guide left ventricular catheter manipulation: feasibility in a porcine model of healed myocardial infarction. *J Am Coll Cardiol* 2004;44:2202-13.
148. Doppalapudi H, Yamada T, McElderry T, Plumb V, Epstein A, Kay G. Ventricular tachycardia originating from the posterior papillary muscle in the left ventricle: a distinct clinical syndrome. *Circ Arrhythmia Electrophysiol* 2008;1: 23-9.
149. Good E, Desjardins B, Jongnarangsin K, Oral H, Chugh A, Ebinger M, Pelosi F et al. Ventricular arrhythmias originating from a papillary muscle in patients without prior infarction: a comparison with fascicular arrhythmias. *Heart Rhythm* 2008;5:1530-7.
150. Okumura Y, Henz B, Johnson S, Bunch TJ, O'Brien C, Hodge D et al. Three-dimensional ultrasound for image-guided mapping and intervention: methods, quantitative validation, and clinical feasibility of a novel multimodality image mapping system. *Circ Arrhythmia Electrophysiol* 2008;1:110-9.
151. Srivathsan K, Bunch TJ, Asirvatham S, Edwards W, Friedman PA, Munger TM et al. Mechanisms and utility of discrete great arterial potentials in the ablation of outflow tract ventricular arrhythmias. *Circ Arrhythmia Electrophysiol* 2008; 1:30-8.
152. Vaseghi M, Cesario DA, Mahajan A, Wiener I, Boyle NG, Fishbein MC et al.

- Catheter ablation of right ventricular outflow tract tachycardia: value of defining coronary anatomy. *J Cardiovasc Electrophysiol* 2006;17:632–7.
153. Abbara S, Desai JC, Cury RC, Butler J, Nieman K, Reddy V. Mapping epicardial fat with multi-detector computed tomography to facilitate percutaneous transcatheter ablation. *Eur J Radiol* 2006;57:417–22.
154. Haines DE. The biophysics of radiofrequency catheter ablation in the heart: the importance of temperature monitoring. *Pacing Clin Electrophysiol* 1993;16:586–91.
155. Matsudaira K, Nakagawa H, Wittkampf FH, Yamanashi WS, Imai S, Pitha JV et al. High incidence of thrombus formation without impedance rise during radiofrequency ablation using electrode temperature control. *Pacing Clin Electrophysiol* 2003;26:1227–37.
156. Nakagawa H, Yamanashi WS, Pitha JV, Arruda M, Wang X, Ohtomo K et al. Comparison of in vivo tissue temperature profile and lesion geometry for radiofrequency ablation with a saline-irrigated electrode versus temperature control in a canine thigh muscle preparation. *Circulation* 1995;91:2264–73.
157. Soejima K, Delacretaz E, Suzuki M, Bruckhorst CB, Maisel WH, Friedman PL et al. Saline-cooled versus standard radiofrequency catheter ablation for infarct-related ventricular tachycardias. *Circulation* 2001;103:1858–62.
158. Yokoyama K, Nakagawa H, Wittkampf FH, Pitha JV, Lazzara R, Jackman WM. Comparison of electrode cooling between internal and open irrigation in radio frequency ablation lesion depth and incidence of thrombus and steam pop. *Circulation* 2006;113:11–9.
159. Seiler J, Roberts-Thomson KC, Raymond JM, Vest J, Delacretaz E, Stevenson WG. Steam pops during irrigated radiofrequency ablation: feasibility of impedance monitoring for prevention. *Heart Rhythm* 2008;5:1411–6.
160. Calkins H, Epstein A, Packer D, Arria AM, Hummel J, Gilligan DM et al. Catheter ablation of ventricular tachycardia in patients with structural heart disease using cooled radiofrequency energy: results of a prospective multicenter study. Cooled RF Multi-Center Investigators Group. *J Am Coll Cardiol* 2000;35:1905–14.
161. Cooper JM, Sapp JL, Tedrow U, Pellegrini CP, Robinson D, Epstein LM et al. Ablation with an internally irrigated radiofrequency catheter: learning how to avoid steam pops. *Heart Rhythm* 2004;1:329–33.
162. Hsu LF, Jais P, Hocini M, Sanders P, Scavee C, Sacher F et al. Incidence and prevention of cardiac tamponade complicating ablation for atrial fibrillation. *Pacing Clin Electrophysiol* 2005;28(Suppl. 1):S106–9.
163. D'Avila A, Thiagalingam A, Holmvang G, Houghtaling C, Ruskin JN, Reddy VY. What is the most appropriate energy source for aortic cusp ablation? A comparison of standard RF, cooled-tip RF and cryothermal ablation. *J Interv Card Electrophysiol* 2006;16:31–8.
164. Obel OA, D'Avila A, Neuzil P, Saad EB, Ruskin JN, Reddy VY. Ablation of left ventricular epicardial outflow tract tachycardia from the distal great cardiac vein. *J Am Coll Cardiol* 2006;48:1813–7.
165. D'Avila A, Houghtaling C, Gutierrez P, Vragovic O, Ruskin JN, Josephson ME et al. Catheter ablation of ventricular epicardial tissue: a comparison of standard and cooled-tip radiofrequency energy. *Circulation* 2004;109:2363–9.
166. D'Avila A, Aryana A, Thiagalingam A, Holmvang G, Schmidt E, Gutierrez P et al. Focal and linear endocardial and epicardial catheter-based cryoablation of normal and infarcted ventricular tissue. *Pacing Clin Electrophysiol* 2008;31:1322–31.
167. Aoyama H, Nakagawa H, Pitha JV, Khammar GS, Chandrasekaran K, Matsudaira K et al. Comparison of cryothermia and radiofrequency current in safety and efficacy of catheter ablation within the canine coronary sinus close to the left circumflex coronary artery. *J Cardiovasc Electrophysiol* 2005;16:1218–26.
168. Lustgarten DL, Keane D, Ruskin J. Cryothermal ablation: mechanism of tissue injury and current experience in the treatment of tachyarrhythmias. *Prog Cardiovasc Dis* 1999;41:481–98.
169. Kirsh JA, Gross GJ, O'Connor S, Hamilton RM. Transcatheter cryoablation of tachyarrhythmias in children: initial experience from an international registry. *J Am Coll Cardiol* 2005;45:133–6.
170. Bhavani SS, Tchou P, Chung M, Fahmy T, Gillinov AM. Intraoperative electroanatomical mapping and beating heart ablation of ventricular tachycardia. *Ann Thorac Surg* 2006;82:1091–3.
171. Braun MU, Knaut M, Rauwolf T, Strasser RH. Microwave ablation of an ischemic sustained ventricular tachycardia during aortocoronary bypass, mitral valve and tricuspid valve surgery guided by a three-dimensional non-fluoroscopic mapping system (CARTO). *J Interv Card Electrophysiol* 2005;13:243–7.
172. Kovoor P, Daly M, Campbell C, Dewsnap B, Eipper V, Uther J et al. Intramural radiofrequency ablation: effects of electrode temperature and length. *Pacing Clin Electrophysiol* 2004;27(6 Pt 1):719–25.
173. Pfeiffer D, Moosdorf R, Svenson RH, Littmann L, Grimm W, Kirchhoff PG et al. Epicardial neodymium. YAG laser photocoagulation of ventricular tachycardia without ventriculotomy in patients after myocardial infarction. *Circulation* 1996;94:3221–5.
174. Sapp JL, Cooper JM, Zei P, Stevenson WG. Large radiofrequency ablation lesions can be created with a retractable infusion-needle catheter. *J Cardiovasc Electrophysiol* 2006;17:657–61.
175. Svenson RH, Littmann L, Colavita PG, Zimmern SH, Gallagher JJ, Fedor JM et al. Laser photoablation of ventricular tachycardia: correlation of diastolic activation times and photoablation effects on cycle length and termination—observations supporting a macroreentrant mechanism. *J Am Coll Cardiol* 1992;19:607–13.
176. Blanc JJ, Almendral J, Brignole M, Fatemi M, Gjesdal K, Gonzalez-Torrecilla E et al. Consensus document on antithrombotic therapy in the setting of electrophysiological procedures. *Europace* 2008;10:513–27.
177. Zhou L, Keane D, Reed G, Ruskin J. Thromboembolic complications of cardiac radiofrequency catheter ablation: a review of the reported incidence, pathogenesis and current research directions. *J Cardiovasc Electrophysiol* 1999;10:611–20.
178. Borger van der Burg AE, de Groot NM, Van Erven L, Bootsma M, van der Wall EE, Schalij MJ. Long-term follow-up after radiofrequency catheter ablation of ventricular tachycardia: a successful approach? *J Cardiovasc Electrophysiol* 2002;13:417–23.
179. Callans DJ, Zado E, Sarter BH, Schwartzman D, Gottlieb CD, Marchlinski FE. Efficacy of radiofrequency catheter ablation for ventricular tachycardia in healed myocardial infarction. *Am J Cardiol* 1998;82:429–32.
180. Della BP, De Ponti R, Uriarte JA, Tondo C, Klersy C, Carbucicchio C et al. Catheter ablation and antiarrhythmic drugs for haemodynamically tolerated post-infarction ventricular tachycardia: long-term outcome in relation to acute electrophysiological findings. *Eur Heart J* 2002;23:414–24.
181. Kim YH, Sosa-Suarez G, Trouton TG, O'Nunain SS, Osswald S, McGovern BA et al. Treatment of ventricular tachycardia by transcatheter radiofrequency ablation in patients with ischemic heart disease. *Circulation* 1994;89:1094–102.
182. Morady F, Harvey M, Kalbfleisch SJ, el-Atassi R, Calkins H, Langberg JJ. Radiofrequency catheter ablation of ventricular tachycardia in patients with coronary artery disease. *Circulation* 1993;87:363–72.
183. O'Callaghan PA, Poloniecki J, Sosa-Suarez G, Ruskin JN, McGovern BA, Garan H. Long-term clinical outcome of patients with prior myocardial infarction after palliative radiofrequency catheter ablation for frequent ventricular tachycardia. *Am J Cardiol* 2001;87:975–979.
184. O'Donnell D, Bourke JP, Anilkumar R, Simeonidou E, Furniss SS. Radiofrequency ablation for post infarction ventricular tachycardia. Report of a single centre experience of 112 cases. *Eur Heart J* 2002;23:1699–705.
185. Ortiz M, Almendral J, Villacastin J, Arenal A, Martinez-Sande JL, Perez-Castellano N et al. Radiofrequency ablation of ventricular tachycardia in patients with ischemic cardiopathy. *Rev Esp Cardiol* 1999;52:159–68.
186. Rothman SA, Hsia HH, Cossu SF, Chmielewski IL, Buxton AE, Miller JM. Radiofrequency catheter ablation of postinfarction ventricular tachycardia: long-term success and the significance of inducible nonclinical arrhythmias. *Circulation* 1997;96:3499–508.
187. Fuster V, Ryden LE, Cannom DS, Crijns HJ, Curtis AB, Ellenbogen KA et al. ACC/AHA/ESC 2006 Guidelines for the Management of Patients with Atrial Fibrillation: a report of the American College of Cardiology/American Heart Association Task Force on Practice Guidelines and the European Society of Cardiology Committee for Practice Guidelines (Writing Committee to Revise the 2001 Guidelines for the Management of Patients With Atrial Fibrillation): developed in collaboration with the European Heart Rhythm Association and the Heart Rhythm Society. *Circulation* 2006;114:e257–354.
188. Statement on Granting Privileges for Administration of Moderate Sedation to Practitioners Who Are Not Anesthesia Professionals. Approved by House of Delegates on 25 October 2005, and amended on 18 October 2006. ASA Standards, Guidelines and Statements; 2009. pp. 43–8.
189. Bubien RS, Fisher JD, Gentzel JA, Murphy EK, Irwin ME, Shea JB et al. NASPE expert consensus document: use of i.v. (conscious) sedation/analgesia by nonanesthesia personnel in patients undergoing arrhythmia specific diagnostic, therapeutic, and surgical procedures. *Pacing Clin Electrophysiol* 1998;21:375–85.
190. Srinivasa V, Kodali BS. Capnometry in the spontaneously breathing patient. *Curr Opin Anaesthesiol* 2004;17:517–20.
191. Erb TO, Kanter RJ, Hall JM, Gan TJ, Kern FH, Schulman SR. Comparison of electrophysiologic effects of propofol and isoflurane-based anesthetics in children undergoing radiofrequency catheter ablation for supraventricular tachycardia. *Anesthesiology* 2002;96:1386–94.
192. Lavoie J, Walsh EP, Burrows FA, Laussen P, Lulu JA, Hansen DD. Effects of propofol or isoflurane anesthesia on cardiac conduction in children undergoing radiofrequency catheter ablation for tachydysrhythmias. *Anesthesiology* 1995;82:884–87.
193. Hief C, Borggrefe M, Chen X, Martinez-Rubio A, Hachenberg T, Lawin P et al.

- Effects of enflurane on inducibility of ventricular tachycardia. *Am J Cardiol* 1991;68:609–13.
194. Denniss AR, Richards DA, Taylor AT, Uther JB. Halothane anesthesia reduces inducibility of ventricular tachyarrhythmias in chronic canine myocardial infarction. *Basic Res Cardiol* 1989;84:5–12.
 195. Seidl K, Hauer B, Schwick NG, Zahn R, Senges J. Comparison of metoprolol and sotalol in preventing ventricular tachyarrhythmias after the implantation of a cardioverter/defibrillator. *Am J Cardiol* 1998;82:744–8.
 196. Garcia FC, Valles E, Dhruvakumar S, Marchlinski FE. Ablation of ventricular tachycardia. *Herzschrittmacherther Elektrophysiol* 2007;18:225–33.
 197. Hinkle DA, Raizen DM, McGarvey ML, Liu GT. Cerebral air embolism complicating cardiac ablation procedures. *Neurology* 2001;56:792–4.
 198. Jongbloed MR, Bax JJ, van der Burg AE, van der Wall EE, Schalij MJ. Radiofrequency catheter ablation of ventricular tachycardia guided by intracardiac echocardiography. *Eur J Echocardiogr* 2004;5:34–40.
 199. Khan HH, Maisel WH, Ho C, Suzuki M, Solomon S, Stevenson WG. Effect of radiofrequency catheter ablation of ventricular tachycardia on left ventricular function in patients with prior myocardial infarction. *J Interv Card Electrophysiol* 2002;7:243–7.
 200. Scanavacca M, D'Avila A, Velarde JL, Reolao JB, Sosa E. Reduction of radiation exposure time during catheter ablation with the use of pulsed fluoroscopy. *Int J Cardiol* 1998;63:71–4.
 201. Corrado D, Basso C, Leoni L, Tokajuk B, Turrini P, Bauce B et al. Three-dimensional electroanatomical voltage mapping and histologic evaluation of myocardial substrate in right ventricular outflow tract tachycardia. *J Am Coll Cardiol* 2008;51:731–9.
 202. Tandri H, Saranathan M, Rodriguez ER, Martinez C, Bomma C, Nasir K et al. Noninvasive detection of myocardial fibrosis in arrhythmogenic right ventricular cardiomyopathy using delayed-enhancement magnetic resonance imaging. *J Am Coll Cardiol* 2005;45:98–103.
 203. Hsia HH, Marchlinski FE. Characterization of the electroanatomic substrate for monomorphic ventricular tachycardia in patients with nonischemic cardiomyopathy. *Pacing Clin Electrophysiol* 2002;25:1114–27.
 204. Kwon DH, Setser RM, Popovic ZB, Thamilarasan M, Sola S, Schoenhagen P et al. Association of myocardial fibrosis, electrocardiography and ventricular tachyarrhythmia in hypertrophic cardiomyopathy: a delayed contrast enhanced MRI study. *Int J Cardiovasc Imaging* 2008;24:617–25.
 205. Suk T, Edwards C, Hart H, Christiansen JP. Myocardial scar detected by contrast-enhanced cardiac magnetic resonance imaging is associated with ventricular tachycardia in hypertrophic cardiomyopathy patients. *Heart Lung Circ* 2008; 17:370–4.
 206. de Roos A, van Rossum AC, van der Wall E, Postema S, Doornbos J, Matheijssen N et al. Reperused and nonreperused myocardial infarction: diagnostic potential of Gd-DTPA-enhanced MR imaging. *Radiology* 1989;172:717–20.
 207. Kim RJ, Wu E, Rafael A, Chen EL, Parker MA, Simonetti O et al. The use of contrast-enhanced magnetic resonance imaging to identify reversible myocardial dysfunction. *N Engl J Med* 2000;343:1445–53.
 208. Lima JA, Judd RM, Bazille A, Schulman SP, Atalar E, Zerhouni EA. Regional heterogeneity of human myocardial infarcts demonstrated by contrast-enhanced MRI. Potential mechanisms. *Circulation* 1995;92:1117–25.
 209. Tscholakoff D, Higgins CB, Sechtem U, McNamara MT. Occlusive and reperused myocardial infarcts: effect of Gd-DTPA on ECG-gated MR imaging. *Radiology* 1986;160:515–9.
 210. Vignaux O, Dhote R, Duboc D, Blanche P, Devaux J, Weber S et al. Detection of myocardial involvement in patients with sarcoidosis applying T2-weighted, contrast-enhanced, and cine magnetic resonance imaging: initial results of a prospective study. *J Comput Assist Tomogr* 2002;26:762–7.
 211. Weinsaft JW, Kim HW, Shah DJ, Klem I, Crowley AL, Brosnan R et al. Detection of left ventricular thrombus by delayed-enhancement cardiovascular magnetic resonance prevalence and markers in patients with systolic dysfunction. *J Am Coll Cardiol* 2008;52:148–157.
 212. Josephson ME. *Clinical Cardiac Electrophysiology: Techniques and Interpretations*. 4th ed. Philadelphia: Lippincott Williams and Wilkins; 2008.
 213. de Bakker JM, Hauer RN, Simmers TA. Activation mapping: unipolar versus bipolar recording. In: Zipes DP, Jalife J eds. *Cardiac Electrophysiology: From Cell to Bedside*. 2nd ed. Philadelphia, PA: WB Saunders; 1995. 1068.
 214. Delacretaz E, Soejima K, Ghitipaty VK, Brunckhorst CB, Friedman PL, Stevenson WG. Single catheter determination of local electrogram prematurity using simultaneous unipolar and bipolar recordings to replace the surface ECG as a timing reference. *Pacing Clin Electrophysiol* 2001;24(Pt 1):441–9.
 215. Stevenson WG, Soejima K. Recording techniques for clinical electrophysiology. *J Cardiovasc Electrophysiol* 2005;16:1017–22.
 216. Tung S, Soejima K, Maisel WH, Suzuki M, Epstein L, Stevenson WG. Recognition of far-field electrograms during entrainment mapping of ventricular tachycardia. *J Am Coll Cardiol* 2003;42:110–5.
 217. Gardner PI, Ursell PC, Fenoglio JJ Jr, Wit AL. Electrophysiologic and anatomic basis for fractionated electrograms recorded from healed myocardial infarcts. *Circulation* 1985;72:596–611.
 218. Cassidy DM, Vassallo JA, Marchlinski FE, Buxton AE, Untereker WJ, Josephson ME. Endocardial mapping in humans in sinus rhythm with normal left ventricles: activation patterns and characteristics of electrograms. *Circulation* 1984;70:37–42.
 219. Bogun F, Kim HM, Han J, Tamirisa K, Tschopp D, Reich S et al. Comparison of mapping criteria for hemodynamically tolerated, postinfarction ventricular tachycardia. *Heart Rhythm* 2006;3:20–26.
 220. Miller JM, Harken AH, Hargrove WC, Josephson ME. Pattern of endocardial activation during sustained ventricular tachycardia. *J Am Coll Cardiol* 1985;6: 1280–7.
 221. Miller JM, Marchlinski FE, Buxton AE, Josephson ME. Relationship between the 12-lead electrocardiogram during ventricular tachycardia and endocardial site of origin in patients with coronary artery disease. *Circulation* 1988;77:759–66.
 222. Bogun F, Bahu M, Knight BP, Weiss R, Paladino W, Harvey M et al. Comparison of effective and ineffective target sites that demonstrate concealed entrainment in patients with coronary artery disease undergoing radiofrequency ablation of ventricular tachycardia. *Circulation* 1997;95:183–90.
 223. El-Shalakany A, Hadjis T, Papageorgiou P, Monahan K, Epstein L, Josephson ME. Entrainment/mapping criteria for the prediction of termination of ventricular tachycardia by single radiofrequency lesion in patients with coronary artery disease. *Circulation* 1999;99:2283–9.
 224. Bogun F, Knight B, Goyal R, Michaud GF, Strickberger SA, Hohnloser SH et al. Discrete systolic potentials during ventricular tachycardia in patients with prior myocardial infarction. *J Cardiovasc Electrophysiol* 1999;10:364–9.
 225. Bogun F, Bahu M, Knight BP, Weiss R, Goyal R, Daoud E et al. Response to pacing at sites of isolated diastolic potentials during ventricular tachycardia in patients with previous myocardial infarction. *J Am Coll Cardiol* 1997;30:505–13.
 226. Josephson ME, Waxman HL, Cain ME, Gardner MJ, Buxton AE. Ventricular activation during ventricular endocardial pacing. II. Role of pace-mapping to localize origin of ventricular tachycardia. *Am J Cardiol* 1982;50:11–22.
 227. Kadish AH, Schmaltz S, Morady F. A comparison of QRS complexes resulting from unipolar and bipolar pacing: implications for pace-mapping. *Pacing Clin Electrophysiol* 1991;14(Pt 1):823–32.
 228. Stevenson WG, Sager PT, Natterson PD, Saxon LA, Middlekauff HR, Wiener I. Relation of pace mapping QRS configuration and conduction delay to ventricular tachycardia reentry circuits in human infarct scars. *J Am Coll Cardiol* 1995;26:481–8.
 229. Meesmann M, Marchlinski FE. Effect of pacing current strength on indices of myocardial activation in man: influence of chronic infarction and polarity of pacing. *J Am Coll Cardiol* 1990;15:393–401.
 230. Sarrazin JF, Kuehne M, Wells D, Chalfoun N, Crawford T, Boonyapisit W et al. High-output pacing in mapping of postinfarction ventricular tachycardia. *Heart Rhythm* 2008;5:1709–14.
 231. Neil R, Brysiewicz B, Mark A. Initial experience with automated pacemapping for localization of ventricular tachycardia. *Heart Rhythm* 2007;4:PO5–11.
 232. SippensGroenewegen A, Spekhorst H, van Hemel NM, Kingma JH, Hauer RN, de Bakker JM et al. Localization of the site of origin of postinfarction ventricular tachycardia by endocardial pace mapping. Body surface mapping compared with the 12-lead electrocardiogram. *Circulation* 1993;88(Pt 1):2290–306.
 233. Azegami K, Wilber DJ, Arruda M, Lin AC, Denman RA. Spatial resolution of pacemapping and activation mapping in patients with idiopathic right ventricular outflow tract tachycardia. *J Cardiovasc Electrophysiol* 2005;16:823–9.
 234. Bogun F, Taj M, Ting M, Kim HM, Reich S, Good E et al. Spatial resolution of pace mapping of idiopathic ventricular tachycardia/ectopy originating in the right ventricular outflow tract. *Heart Rhythm* 2008;5:339–44.
 235. Brunckhorst CB, Stevenson WG, Soejima K, Maisel WH, Delacretaz E, Friedman PL et al. Relationship of slow conduction detected by pace-mapping to ventricular tachycardia re-entry circuit sites after infarction. *J Am Coll Cardiol* 2003;41:802–9.
 236. Almendral JM, Gottlieb CD, Rosenthal ME, Stamato NJ, Buxton AE, Marchlinski FE et al. Entrainment of ventricular tachycardia: explanation for surface electrocardiographic phenomena by analysis of electrograms recorded within the tachycardia circuit. *Circulation* 1988;77:569–80.
 237. Callans DJ, Zardini M, Gottlieb CD, Josephson ME. The variable contribution of functional and anatomic barriers in human ventricular tachycardia: an analysis with resetting from two sites. *J Am Coll Cardiol* 1996;27:1106–11.
 238. Kocovic DZ, Harada T, Friedman PL, Stevenson WG. Characteristics of electrograms recorded at reentry circuit sites and bystanders during ventricular tachycardia after myocardial infarction. *J Am Coll Cardiol* 1999;34:381–8.
 239. Morady F, Frank R, Kou WH, Tonet JL, Nelson SD, Kounde S et al. Identifi-

- cation and catheter ablation of a zone of slow conduction in the reentrant circuit of ventricular tachycardia in humans. *J Am Coll Cardiol* 1988;11:775–82.
240. Nitta T, Schuessler RB, Mitsuno M, Rokkas CK, Isobe F, Cronin CS et al. Return cycle mapping after entrainment of ventricular tachycardia. *Circulation* 1998;97:1164–75.
 241. Okumura K, Olshansky B, Henthorn RW, Epstein AE, Plumb VJ, Waldo AL. Demonstration of the presence of slow conduction during sustained ventricular tachycardia in man: use of transient entrainment of the tachycardia. *Circulation* 1987;75:369–78.
 242. Rosenthal ME, Stamato NJ, Almendral JM, Gottlieb CD, Josephson ME. Resetting of ventricular tachycardia with electrocardiographic fusion: incidence and significance. *Circulation* 1988;77:581–8.
 243. Stevenson WG, Friedman PL, Sager PT, Saxon LA, Kocovic D, Harada T et al. Exploring postinfarction reentrant ventricular tachycardia with entrainment mapping. *J Am Coll Cardiol* 1997;29:1180–9.
 244. Khan HH, Stevenson WG. Activation times in and adjacent to reentry circuits during entrainment: implications for mapping ventricular tachycardia. *Am Heart J* 1994;127(Pt 1):833–42.
 245. Hadjis TA, Harada T, Stevenson WG, Friedman PL. Effect of recording site on postpacing interval measurement during catheter mapping and entrainment of postinfarction ventricular tachycardia. *J Cardiovasc Electrophysiol* 1997;8:398–404.
 246. Soejima K, Stevenson WG, Maisel WH, Delacretaz E, Brunckhorst CB, Ellison KE et al. The N + 1 difference: a new measure for entrainment mapping. *J Am Coll Cardiol* 2001;37:1386–94.
 247. Fontaine G, Evans S, Frank R, Tonet J, Iwa T, Lascault G et al. Ventricular tachycardia overdrive and entrainment with and without fusion: its relevance to the catheter ablation of ventricular tachycardia. *Clin Cardiol* 1990;13:797–803.
 248. Ormaetxe JM, Almendral J, Martinez-Alday JD, Villacastin JP, Arenal A, Pastor A et al. Analysis of the degree of QRS fusion necessary for its visual detection: importance for the recognition of transient entrainment. *Circulation* 1997;96:3509–16.
 249. Morady F, Kadish A, Rosenheck S, Calkins H, Kou WH, de Buitler M et al. Concealed entrainment as a guide for catheter ablation of ventricular tachycardia in patients with prior myocardial infarction. *J Am Coll Cardiol* 1991;17:678–89.
 250. Arenal A, del Castillo S, Gonzalez-Torrecilla E, Atienza F, Ortiz M, Jimenez J et al. Tachycardia-related channel in the scar tissue in patients with sustained monomorphic ventricular tachycardias: influence of the voltage scar definition. *Circulation* 2004;110:2568–74.
 - 250a. Ciaccio EJ, Chow AW, Kaba RA, Davies DW, Segal OR, Peters NS. Detection of the diastolic pathway, circuit morphology, and inducibility of human postinfarction ventricular tachycardia from mapping in sinus rhythm. *Heart Rhythm* 2008;5:981–91.
 251. Cesario DA, Vaseghi M, Boyle NG, Fishbein MC, Valderrabano M, Narasimhan C et al. Value of high-density endocardial and epicardial mapping for catheter ablation of hemodynamically unstable ventricular tachycardia. *Heart Rhythm* 2006;3:1–10.
 252. Li YG, Gronefeld G, Israel C, Lu SB, Wang QS, Meng S et al. Stepwise approach to substrate modification of ventricular tachycardia after myocardial infarction. *Chin Med J (Engl)* 2006;119:1182–9.
 253. Oza S, Wilber DJ. Substrate-based endocardial ablation of postinfarction ventricular tachycardia. *Heart Rhythm* 2006;3:607–9.
 254. Volkmer M, Ouyang F, Deger F, Ernst S, Goya M, Bansch D et al. Substrate mapping vs. tachycardia mapping using CARTO in patients with coronary artery disease and ventricular tachycardia: impact on outcome of catheter ablation. *Europace* 2006;8:968–76.
 255. Zeppenfeld K, Kies P, Wijffels MC, Bootsma M, van Erven L, Schalij MJ. Identification of successful catheter ablation sites in patients with ventricular tachycardia based on electrogram characteristics during sinus rhythm. *Heart Rhythm* 2005;2:940–50.
 256. Callans DJ, Ren JF, Michele J, Marchlinski FE, Dillon SM. Electroanatomic left ventricular mapping in the porcine model of healed anterior myocardial infarction. Correlation with intracardiac echocardiography and pathological analysis. *Circulation* 1999;100:1744–50.
 257. Della BP, Riva S, Fassini G, Giraldo F, Berti M, Klersy C et al. Incidence and significance of pleomorphism in patients with postmyocardial infarction ventricular tachycardia. Acute and long-term outcome of radiofrequency catheter ablation. *Eur Heart J* 2004;25:1127–38.
 258. O'Donnell D, Bourke JP, Furniss SS. Standardized stimulation protocol to predict the long-term success of radiofrequency ablation of postinfarction ventricular tachycardia. *Pacing Clin Electrophysiol* 2003;26(Pt 2):348–51.
 259. Gonska BD, Cao K, Schaumann A, Dorszewski A, von zur MF, Kreuzer H. Catheter ablation of ventricular tachycardia in 136 patients with coronary artery disease: results and long-term follow-up. *J Am Coll Cardiol* 1994;24:1506–14.
 260. Ventura R, Klemm HU, Rostock T, Lutomsky B, Rissius T, Steven D et al. Stable and unstable ventricular tachycardias in patients with previous myocardial infarction: a clinically oriented strategy for catheter ablation. *Cardiology* 2008;109:52–61.
 261. Deneke T, Grewe PH, Lawo T, Calcum B, Mugge A, Lemke B. Substrate-modification using electroanatomical mapping in sinus rhythm to treat ventricular tachycardia in patients with ischemic cardiomyopathy. *Z Kardiol* 2005;94:453–60.
 262. Carubicchio C, Santamaria M, Trevisi N, Maccabelli G, Giraldo F, Fassini G et al. Catheter ablation for the treatment of electrical storm in patients with implantable cardioverter-defibrillators: short- and long-term outcomes in a prospective single-center study. *Circulation* 2008;117:462–9.
 263. Harada T, Stevenson WG, Kocovic DZ, Friedman PL. Catheter ablation of ventricular tachycardia after myocardial infarction: relation of endocardial sinus rhythm late potentials to the reentry circuit. *J Am Coll Cardiol* 1997;30:1015–23.
 264. Marrouche NF, Verma A, Wazni O, Schweikert R, Martin DO, Saliba W et al. Mode of initiation and ablation of ventricular fibrillation storms in patients with ischemic cardiomyopathy. *J Am Coll Cardiol* 2004;43:1715–20.
 265. Szumowski L, Sanders P, Walczak F, Hocini M, Jais P, Kepski R et al. Mapping and ablation of polymorphic ventricular tachycardia after myocardial infarction. *J Am Coll Cardiol* 2004;44:1700–6.
 266. Brugada J, Berrueto A, Cuesta A, Osca J, Chueca E, Fosch X et al. Nonsurgical transthoracic epicardial radiofrequency ablation: an alternative in incessant ventricular tachycardia. *J Am Coll Cardiol* 2003;41:2036–43.
 267. Sosa E, Scanavacca M, D'Avila A, Pilleggi F. A new technique to perform epicardial mapping in the electrophysiology laboratory. *J Cardiovasc Electrophysiol* 1996; 7:531–6.
 268. Spielman SR. Activation mapping in ventricular tachycardia: role of the epicardium. *J Am Coll Cardiol* 1990;15:171–3.
 269. D'Avila A et al. Epicardial VT ablation. A multicenter safety study. 2009 (in press).
 270. D'Avila A. Epicardial catheter ablation of ventricular tachycardia. *Heart Rhythm* 2008;5:S73–5.
 271. Sosa E, Scanavacca M, D'Avila A, Antonio J, Ramires F. Nonsurgical transthoracic epicardial approach in patients with ventricular tachycardia and previous cardiac surgery. *J Interv Card Electrophysiol* 2004;10:281–8.
 272. Soejima K, Couper G, Cooper JM, Sapp JL, Epstein LM, Stevenson WG. Subxiphoid surgical approach for epicardial catheter-based mapping and ablation in patients with prior cardiac surgery or difficult pericardial access. *Circulation* 2004;110:1197–201.
 273. Villacastin J, Perez CN, Moreno J, Alvarez L, Moreno M, Quintana J. [Percutaneous epicardial radiofrequency ablation of idiopathic ventricular tachycardia]. *Rev Esp Cardiol* 2005;58:100–4.
 274. D'Avila A, Gutierrez P, Scanavacca M, Reddy V, Lustgarten DL, Sosa E et al. Effects of radiofrequency pulses delivered in the vicinity of the coronary arteries: implications for nonsurgical transthoracic epicardial catheter ablation to treat ventricular tachycardia. *Pacing Clin Electrophysiol* 2002;25:1488–95.
 275. Sosa E, Scanavacca M. Epicardial mapping and ablation techniques to control ventricular tachycardia. *J Cardiovasc Electrophysiol* 2005;16:449–52.
 276. Sosa E, Scanavacca M, D'Avila A. Transthoracic epicardial catheter ablation to treat recurrent ventricular tachycardia. *Curr Cardiol Rep* 2001;3:451–8.
 277. Demaria RG, Page P, Leung TK, Dubuc M, Malo O, Carrier M et al. Surgical radiofrequency ablation induces coronary endothelial dysfunction in porcine coronary arteries. *Eur J Cardiothorac Surg* 2003;23:277–82.
 278. Thyer IA, Kovoor P, Barry MA, Poulipoulos J, Ross DL, Thiagalingam A. Protection of the coronary arteries during epicardial radiofrequency ablation with intracoronary chilled saline irrigation: assessment in an in vitro model. *J Cardiovasc Electrophysiol* 2006;17:544–9.
 279. Lustgarten DL, Bell S, Hardin N, Calame J, Spector PS. Safety and efficacy of epicardial cryoablation in a canine model. *Heart Rhythm* 2005;2:82–90.
 280. Bai R, Patel D, Di BL, Fahmy TS, Kozeluhova M, Prasad S et al. Phrenic nerve injury after catheter ablation: should we worry about this complication? *J Cardiovasc Electrophysiol* 2006;17:944–8.
 281. Fan R, Cano O, Ho SY, Bala R, Callans DJ, Dixit S et al. Characterization of the phrenic nerve course within the epicardial substrate of patients with nonischemic cardiomyopathy and ventricular tachycardia. *Heart Rhythm* 2009;6:59–64.
 282. Buch E, Vaseghi M, Cesario DA, Shivkumar K. A novel method for preventing phrenic nerve injury during catheter ablation. *Heart Rhythm* 2007;4:95–8.
 283. Matsuo S, Jais P, Knecht S, Lim KT, Hocini M, Derval N et al. Images in cardiovascular medicine. Novel technique to prevent left phrenic nerve injury during epicardial catheter ablation. *Circulation* 2008;117:e471.
 284. Yamada T, McElderry HT, Platonov M, Doppalapudi H, Kay GN. Aspirated air in the pericardial space during epicardial catheterization may elevate the defibrillation threshold. *Int J Cardiol; Epub ahead of print* 30 June 2008, doi: 10.1016/j.ijcard.2008.03.074.

285. D'Avila A, Neuzil P, Thiagalingam A, Gutierrez P, Aleong R, Ruskin JN et al. Experimental efficacy of pericardial instillation of anti-inflammatory agents during percutaneous epicardial catheter ablation to prevent postprocedure pericarditis. *J Cardiovasc Electrophysiol* 2007;18:1178–83.
286. Bazan V, Bala R, Garcia FC, Sussman JS, Gerstenfeld EP, Dixit S et al. Twelve-lead ECG features to identify ventricular tachycardia arising from the epicardial right ventricle. *Heart Rhythm* 2006;3:1132–9.
287. Bazan V, Gerstenfeld EP, Garcia FC, Bala R, Rivas N, Dixit S et al. Site-specific twelve-lead ECG features to identify an epicardial origin for left ventricular tachycardia in the absence of myocardial infarction. *Heart Rhythm* 2007;4:1403–10.
288. Berrueto A, Mont L, Nava S, Chueca E, Bartholomay E, Brugada J. Electrocardiographic recognition of the epicardial origin of ventricular tachycardias. *Circulation* 2004;109:1842–7.
289. Sosa E, Scanavacca M, D'Avila A, Oliveira F, Ramires JA. Nonsurgical trans-thoracic epicardial catheter ablation to treat recurrent ventricular tachycardia occurring late after myocardial infarction. *J Am Coll Cardiol* 2000;35:1442–9.
290. Verma A, Marrouche NF, Schweikert RA, Saliba W, Wazni O, Cummings J et al. Relationship between successful ablation sites and the scar border zone defined by substrate mapping for ventricular tachycardia post-myocardial infarction. *J Cardiovasc Electrophysiol* 2005;16:465–71.
291. Anh DJ, Hsia HH, Reitz B, Zei P. Epicardial ablation of postinfarction ventricular tachycardia with an externally irrigated catheter in a patient with mechanical aortic and mitral valves. *Heart Rhythm* 2007;4:651–4.
292. Schweikert RA, Saliba W, Tomassoni G, Marrouche NF, Cole CR, Dresing TJ et al. Percutaneous pericardial instrumentation for endo-epicardial mapping of previously failed ablations. *Circulation* 2003;108:1329–35.
293. Daniels DV, Lu YY, Morton JB, Santucci PA, Akar JG, Green A et al. Idiopathic epicardial left ventricular tachycardia originating remote from the sinus of valsalva: electrophysiological characteristics, catheter ablation, and identification from the 12-lead electrocardiogram. *Circulation* 2006;113:1659–66.
294. Doppalapudi H, Yamada T, Ramaswamy K, Ahn J, Kay GN. Idiopathic focal epicardial ventricular tachycardia originating from the crux of the heart. *Heart Rhythm* 2009;6:44–50.
295. Krishnan SC, Josephson ME. Surgery for postinfarction ventricular tachycardia: is it obsolete? *Pacing Clin Electrophysiol* 2000;23:1295–301.
296. Rastegar H, Link MS, Foote CB, Wang PJ, Manolis AS, Estes NA III. Perioperative and long-term results with mapping-guided subendocardial resection and left ventricular endoaneurysmorrhaphy. *Circulation* 1996;94:1041–8.
297. Page PL, Cardinal R, Shenasa M, Kaltenbrunner W, Cossette R, Nadeau R. Surgical treatment of ventricular tachycardia. Regional cryoablation guided by computerized epicardial and endocardial mapping. *Circulation* 1989;80(Pt 1):1124–34.
298. Iwa T, Misaki T, Kawasuji M, Matsunaga Y, Tsubota M, Matsumoto Y. Long-term results of surgery for non-ischemic ventricular tachycardia. *Eur J Cardiothorac Surg* 1991;5:191–97.
299. Karamlou T, Silber I, Lao R, McCrindle BW, Harris L, Downar E et al. Outcomes after late reoperation in patients with repaired tetralogy of Fallot: the impact of arrhythmia and arrhythmia surgery. *Ann Thorac Surg* 2006;81:1786–93.
300. Lawrie GM, Pacifico A, Kaushik R. Results of direct surgical ablation of ventricular tachycardia not due to ischemic heart disease. *Ann Surg* 1989;209:716–27.
301. Brugada P, de Swart H, Smeets JL, Wellens HJ. Transcatheter chemical ablation of ventricular tachycardia. *Circulation* 1989;79:475–82.
302. Inoue H, Waller BF, Zipes DP. Intracoronary ethyl alcohol or phenol injection ablates aconitine-induced ventricular tachycardia in dogs. *J Am Coll Cardiol* 1987;10:1342–9.
303. Kay GN, Epstein AE, Buben RS, Anderson PG, Dailey SM, Plumb VJ. Intracoronary ethanol ablation for the treatment of recurrent sustained ventricular tachycardia. *J Am Coll Cardiol* 1992;19:159–68.
304. Sacher F, Sobieszczek P, Tedrow U, Eisenhauer AC, Field ME, Selwyn A et al. Transcatheter ethanol ventricular tachycardia ablation in the modern electrophysiology era. *Heart Rhythm* 2008;5:62–8.
305. Sosa E, Scanavacca M, D'Avila A, Tondato F, Kuniyoshi R, Elias J. Nonsurgical trans-thoracic mapping and ablation in a child with incessant ventricular tachycardia. *J Cardiovasc Electrophysiol* 2000;11:208–10.
306. Delacretaz E, Seiler J, Tanner H, Hess OM. Ablation of ventricular tachycardia: neither inside nor out, thus back to alcohol. *Heart Rhythm* 2006;3:1230–1.
307. Hess OM, Sigwart U. New treatment strategies for hypertrophic obstructive cardiomyopathy: alcohol ablation of the septum: the new gold standard? *J Am Coll Cardiol* 2004;44:2054–5.
308. Seggewiss H, Gleichmann U, Faber L, Fassbender D, Schmidt HK, Strick S. Percutaneous transluminal septal myocardial ablation in hypertrophic obstructive cardiomyopathy: acute results and 3-month follow-up in 25 patients. *J Am Coll Cardiol* 1998;31:252–8.
309. Sigwart U. Non-surgical myocardial ablation: for hypertrophic obstructive cardiomyopathy. *Cardiologia* 1998;43:157–61.
310. Kim SS, Knight BP. Alcohol ablation for ventricular tachycardia: a distillation of modern cases. *Heart Rhythm* 2008;5:69–70.
311. Akiyama J, Aonuma K, Nogami A, Hiroe M, Marumo F, Iesaka Y. Thrombolytic therapy can reduce the arrhythmogenic substrate after acute myocardial infarction: a study using the signal-averaged electrocardiogram, endocardial catheter mapping and programmed ventricular stimulation. *Jpn Circ J* 1999;63:838–42.
312. Chong JJ, Ganesan AN, Eipper V, Kovoor P. Comparison of left ventricular ejection fraction and inducible ventricular tachycardia in ST-elevation myocardial infarction treated by primary angioplasty versus thrombolysis. *Am J Cardiol* 2008;101:153–7.
313. Wilber DJ, Zareba W, Hall WJ, Brown MW, Lin AC, Andrews ML et al. Time dependence of mortality risk and defibrillator benefit after myocardial infarction. *Circulation* 2004;109:1082–4.
314. Bogun F, Li YG, Groenefeld G, Hohnloser SH, Schuger C, Oral H et al. Prevalence of a shared isthmus in postinfarction patients with pleiomorphic, hemodynamically tolerated ventricular tachycardias. *J Cardiovasc Electrophysiol* 2002;13:237–41.
315. Dalal D, Jain R, Tandri H, Dong J, Eid SM, Prakasa K et al. Long-term efficacy of catheter ablation of ventricular tachycardia in patients with arrhythmogenic right ventricular dysplasia/cardiomyopathy. *J Am Coll Cardiol* 2007;50:432–40.
316. Sra J, Bhatia A, Dhala A, Blanche Z, Deshpande S, Cooley R et al. Electroanatomically guided catheter ablation of ventricular tachycardias causing multiple defibrillator shocks. *Pacing Clin Electrophysiol* 2001;24:1645–52.
317. Bansch D, Oyang F, Antz M, Arentz T, Weber R, Val-Mejias JE et al. Successful catheter ablation of electrical storm after myocardial infarction. *Circulation* 2003; 108:3011–6.
318. Cao K, Gonska BD. Catheter ablation of incessant ventricular tachycardia: acute and long-term results. *Eur Heart J* 1996;17:756–63.
319. Silva RM, Mont L, Nava S, Rojel U, Matas M, Brugada J. Radiofrequency catheter ablation for arrhythmic storm in patients with an implantable cardioverter defibrillator. *Pacing Clin Electrophysiol* 2004;27:971–5.
320. Hsia HH, Callans DJ, Marchlinski FE. Characterization of endocardial electrophysiological substrate in patients with nonischemic cardiomyopathy and monomorphic ventricular tachycardia. *Circulation* 2003;108:704–10.
321. Hoffman JIE. Incidence, mortality, and natural history. In: Anderson RH, Baker EJ, McCarthy FJ, Rigby ML, Shinebourne EA, Tynan M eds. *Paediatric Cardiology*. 2nd ed. London, UK: Churchill Livingstone; 2002. p111–40.
322. Walsh EP. Interventional electrophysiology in patients with congenital heart disease. *Circulation* 2007;115:3224–34.
323. Steeds RP, Oakley D. Predicting late sudden death from ventricular arrhythmia in adults following surgical repair of tetralogy of Fallot. *QJM* 2004;97:7–13.
324. Harrison DA, Siu SC, Hussain F, MacLoughlin CJ, Webb GD, Harris L. Sustained atrial arrhythmias in adults late after repair of tetralogy of fallot. *Am J Cardiol* 2001;87:584–8.
325. Deanfield JE, McKenna WJ, Presbitero P, England D, Graham GR, Hallidie-Smith K. Ventricular arrhythmia in unrepaired and repaired tetralogy of Fallot. Relation to age, timing of repair, and haemodynamic status. *Br Heart J* 1984; 52:77–81.
326. Gatzoulis MA, Balaji S, Webber SA, Siu SC, Hokanson JS, Poile C et al. Risk factors for arrhythmia and sudden cardiac death late after repair of tetralogy of Fallot: a multicentre study. *Lancet* 2000;356:975–81.
327. Khairy P, Harris L, Landzberg MJ, Viswanathan S, Barlow A, Gatzoulis MA et al. Implantable cardioverter-defibrillators in tetralogy of Fallot. *Circulation* 2008;117:363–70.
328. Murphy JG, Gersh BJ, Mair DD, Fuster V, McGoan MD, Ilstrup DM et al. Long-term outcome in patients undergoing surgical repair of tetralogy of Fallot. *N Engl J Med* 1993;329:593–9.
329. Nollert G, Fischlein T, Bouterwek S, Bohmer C, Klinner W, Reichart B. Long-term survival in patients with repair of tetralogy of Fallot: 36-year follow-up of 490 survivors of the first year after surgical repair. *J Am Coll Cardiol* 1997; 30:1374–83.
330. Morwood JG, Triedman JK, Berul CI, Khairy P, Alexander ME, Cecchin F et al. Radiofrequency catheter ablation of ventricular tachycardia in children and young adults with congenital heart disease. *Heart Rhythm* 2004;1:301–8.
331. Zeppenfeld K, Schalij MJ, Bartelings MM, Tedrow UB, Koplman BA, Soejima K et al. Catheter ablation of ventricular tachycardia after repair of congenital heart disease: electroanatomic identification of the critical right ventricular isthmus. *Circulation* 2007;116:2241–52.
332. Biblo LA, Carlson MD. Transcatheter radiofrequency ablation of ventricular

- tachycardia following surgical correction of tetralogy of Fallot. *Pacing Clin Electrophysiol* 1994;17:1556–60.
333. Burton ME, Leon AR. Radiofrequency catheter ablation of right ventricular outflow tract tachycardia late after complete repair of tetralogy of Fallot using the pace mapping technique. *Pacing Clin Electrophysiol* 1993;16:2319–25.
 334. Furushima H, Chinushi M, Sugiyama H, Komura S, Tanabe Y, Watanabe H et al. Ventricular tachycardia late after repair of congenital heart disease: efficacy of combination therapy with radiofrequency catheter ablation and class III antiarrhythmic agents and long-term outcome. *J Electrocardiol* 2006;39:219–24.
 335. Goldner BG, Cooper R, Blau W, Cohen TJ. Radiofrequency catheter ablation as a primary therapy for treatment of ventricular tachycardia in a patient after repair of tetralogy of Fallot. *Pacing Clin Electrophysiol* 1994;17:1441–6.
 336. Gonska BD, Cao K, Raab J, Eigster G, Kreuzer H. Radiofrequency catheter ablation of right ventricular tachycardia late after repair of congenital heart defects. *Circulation* 1996;94:1902–8.
 337. Horton RP, Canby RC, Kessler DJ, Joglar JA, Hume A, Jessen ME et al. Ablation of ventricular tachycardia associated with tetralogy of Fallot: demonstration of bidirectional block. *J Cardiovasc Electrophysiol* 1997;8:432–5.
 338. Muthappan P, Calkins H. Arrhythmogenic right ventricular dysplasia. *Prog Cardiovasc Dis* 2008;51:31–43.
 339. Menz V, Duthinh V, Callans DJ, Schwartzman D, Gottlieb CD, Marchlinski FE. Right ventricular radiofrequency ablation of ventricular tachycardia after myocardial infarction. *Pacing Clin Electrophysiol* 1997;20:1727–31.
 340. Verma A, Kilicaslan F, Schweikert RA, Tomassoni G, Rossillo A, Marrouche NF et al. Short- and long-term success of substrate-based mapping and ablation of ventricular tachycardia in arrhythmogenic right ventricular dysplasia. *Circulation* 2005;111:3209–16.
 341. Bakir I, Brugada P, Sarkozy A, Vandepitte C, Wellens F. A novel treatment strategy for therapy refractory ventricular arrhythmias in the setting of arrhythmogenic right ventricular dysplasia. *Europace* 2007;9:267–9.
 342. O'Donnell D, Cox D, Bourke J, Mitchell L, Furniss S. Clinical and electrophysiological differences between patients with arrhythmogenic right ventricular dysplasia and right ventricular outflow tract tachycardia. *Eur Heart J* 2003;24:801–10.
 343. Nogami A, Sugiyasu A, Tada H, Kurosaki K, Sakamaki M, Kowase S et al. Changes in the isolated delayed component as an endpoint of catheter ablation in arrhythmogenic right ventricular cardiomyopathy. Predictor of long-term success. *J Cardiovasc Electrophysiol* 2008;19:681–8.
 344. Bogun F, Crawford T, Reich S, Koelling TM, Armstrong W, Good E et al. Radiofrequency ablation of frequent, idiopathic premature ventricular complexes: comparison with a control group without intervention. *Heart Rhythm* 2007;4:863–7.
 345. Yarlagadda RK, Iwai S, Stein KM, Markowitz SM, Shah BK, Cheung JW et al. Reversal of cardiomyopathy in patients with repetitive monomorphic ventricular ectopy originating from the right ventricular outflow tract. *Circulation* 2005;112:1092–7.
 346. El-Sherif N. Reentrant ventricular arrhythmias in the late myocardial infarction period. 6. Effect of the autonomic system. *Circulation* 1978;58:103–10.
 347. Bogun F, Crawford T, Chalfoun N, Kuhne M, Sarrazin JF, Wells D et al. Relationship of frequent postinfarction premature ventricular complexes to the reentry circuit of scar-related ventricular tachycardia. *Heart Rhythm* 2008;5:367–74.
 348. Yamada T, Murakami Y, Yoshida N, Okada T, Shimizu T, Toyama J et al. Preferential conduction across the ventricular outflow septum in ventricular arrhythmias originating from the aortic sinus cusp. *J Am Coll Cardiol* 2007;50:884–91.
 349. Yamada T, McElderry HT, Doppalapudi H, Murakami Y, Yoshida Y, Yoshida N et al. Idiopathic ventricular arrhythmias originating from the aortic root prevalence, electrocardiographic and electrophysiologic characteristics, and results of radiofrequency catheter ablation. *J Am Coll Cardiol* 2008;52:139–47.
 350. Blanck Z, Dhala A. Bundle branch reentry: mechanisms, diagnosis, and treatment. In: Zipes DP ed. *Cardiac Electrophysiology: from Cell to Bedside*. Philadelphia: Saunders; 1995. p875–85.
 351. Merino JL, Carmona JR, Fernandez-Lozano I, Peinado R, Basterra N, Sobrino JA. Mechanisms of sustained ventricular tachycardia in myotonic dystrophy: implications for catheter ablation. *Circulation* 1998;98:541–6.
 352. Oretó G, Smeets JL, Rodríguez LM, Timmermans C, Wellens HJ. Wide complex tachycardia with atrioventricular dissociation and QRS morphology identical to that of sinus rhythm: a manifestation of bundle branch reentry. *Heart* 1996;76:541–7.
 353. Blanck Z, Jazayeri M, Dhala A, Deshpande S, Sra J, Akhtar M. Bundle branch reentry: a mechanism of ventricular tachycardia in the absence of myocardial or valvular dysfunction. *J Am Coll Cardiol* 1993;22:1718–22.
 354. Gupta AK, Vajifdar BU, Vora AM. Bundle branch re-entrant ventricular tachycardia in a patient with structurally normal heart. *Indian Heart J* 1999;51:80–2.
 355. Simons GR, Sorrentino RA, Zimerman LI, Wharton JM, Natale A. Bundle branch reentry tachycardia and possible sustained interfascicular reentry tachycardia with a shared unusual induction pattern. *J Cardiovasc Electrophysiol* 1996;7:44–50.
 356. Berger RD, Orias D, Kasper EK, Calkins H. Catheter ablation of coexistent bundle branch and interfascicular reentrant ventricular tachycardias. *J Cardiovasc Electrophysiol* 1996;7:341–7.
 357. Blanck Z, Dhala A, Deshpande S, Sra J, Jazayeri M, Akhtar M. Bundle branch reentrant ventricular tachycardia: cumulative experience in 48 patients. *J Cardiovasc Electrophysiol* 1993;4:253–62.
 358. Josephson ME. *Clinical Cardiac Electrophysiology: Technique and Interpretation*. 3rd ed. Philadelphia: Lippincott Williams and Wilkins; 2002.
 359. Andress JD, Vander Salm TJ, Huang SK. Bidirectional bundle branch reentry tachycardia associated with Ebstein's anomaly: cured by extensive cryoablation of the right bundle branch. *Pacing Clin Electrophysiol* 1991;14(Pt 1):1639–47.
 360. Cohen TJ, Chien WW, Lurie KG, Young C, Goldberg HR, Wang YS et al. Radiofrequency catheter ablation for treatment of bundle branch reentrant ventricular tachycardia: results and long-term follow-up. *J Am Coll Cardiol* 1991;18:1767–73.
 361. Mehdiraz AA, Keim S, Rist K, Tchou P. Long-term clinical outcome of right bundle branch radiofrequency catheter ablation for treatment of bundle branch reentrant ventricular tachycardia. *Pacing Clin Electrophysiol* 1995;18(Pt 1):2135–43.
 362. Mittal S, Coyne RF, Herling IM, Kocovic DZ, Pavri BB. Sustained bundle branch reentry in a patient with hypertrophic cardiomyopathy and nondilated left ventricle. *J Interv Card Electrophysiol* 1997;1:73–7.
 363. Narasimhan C, Jazayeri MR, Sra J, Dhala A, Deshpande S, Biehl M et al. Ventricular tachycardia in valvular heart disease: facilitation of sustained bundle-branch reentry by valve surgery. *Circulation* 1997;96:4307–13.
 364. Negri SM, Cowan MD. Becker muscular dystrophy with bundle branch reentry ventricular tachycardia. *J Cardiovasc Electrophysiol* 1998;9:652–4.
 365. Chalvidan T, Cellarier G, Deharo JC, Colin R, Savon N, Barra N et al. His-Purkinje system reentry as a proarrhythmic effect of flecainide. *Pacing Clin Electrophysiol* 2000;23(Pt 1):530–3.
 366. Saoudi N, Berland J, Cribier A, Letac B. [Bundle branch reentry tachycardia: a possible mechanism of flecainide proarrhythmia effect]. *Arch Mal Coeur Vaiss* 1988;81:537–41.
 367. Li YG, Gronfeld G, Israel C, Bogun F, Hohnloser SH. Bundle branch reentrant tachycardia in patients with apparent normal His–Purkinje conduction: the role of functional conduction impairment. *J Cardiovasc Electrophysiol* 2002;13:1233–9.
 368. Blanck Z, Jazayeri M, Akhtar M. Facilitation of sustained bundle branch reentry by atrial fibrillation. *J Cardiovasc Electrophysiol* 1996;7:348–52.
 369. Merino JL, Peinado R, Fernandez-Lozano I, Lopez-Gil M, Arribas F, Ramirez LJ et al. Bundle-branch reentry and the postpacing interval after entrainment by right ventricular apex stimulation: a new approach to elucidate the mechanism of wide-QRS-complex tachycardia with atrioventricular dissociation. *Circulation* 2001;103:1102–8.
 370. Wilkoff BL, Ousdigian KT, Sterns LD, Wang ZJ, Wilson RD, Morgan JM. A comparison of empiric to physician-tailored programming of implantable cardioverter-defibrillators: results from the prospective randomized multicenter EMPIRIC trial. *J Am Coll Cardiol* 2006;48:330–9.
 371. Santini M, Pandozi C, Ricci R. Combining antiarrhythmic drugs and implantable devices therapy: benefits and outcome. *J Interv Card Electrophysiol* 2000;4(Suppl. 1):65–8.
 372. Nayak HM, Verdino RJ, Russo AM, Gerstenfeld EP, Hsia HH, Lin D et al. Ventricular tachycardia storm after initiation of biventricular pacing: incidence, clinical characteristics, management, and outcome. *J Cardiovasc Electrophysiol* 2008;19:708–15.
 373. Moss AJ, Zareba W, Hall WJ, Klein H, Wilber DJ, Cannom DS et al. Prophylactic implantation of a defibrillator in patients with myocardial infarction and reduced ejection fraction. *N Engl J Med* 2002;346:877–83.
 374. Bardy GH, Lee KL, Mark DB, Poole JE, Packer DL, Boineau R et al. Amiodarone or an implantable cardioverter-defibrillator for congestive heart failure. *N Engl J Med* 2005;352:225–37.
 375. Epstein AE, DiMarco JP, Ellenbogen KA, Estes NA III, Freedman RA, Gettes LS et al. ACC/AHA/HRS 2008 Guidelines for device-based therapy of cardiac rhythm abnormalities. *Heart Rhythm* 2008;5:e1–62.
 376. Ainsworth CD, Skanes AC, Klein GJ, Gula LJ, Yee R, Krahn AD. Differentiating arrhythmogenic right ventricular cardiomyopathy from right ventricular outflow tract ventricular tachycardia using multilead QRS duration and axis. *Heart Rhythm* 2006;3:416–23.
 377. Bunch TJ, Day JD. Right meets left: a common mechanism underlying right and left ventricular outflow tract tachycardias. *J Cardiovasc Electrophysiol* 2006;17:1059–61.

378. Callans DJ, Menz V, Schwartzman D, Gottlieb CD, Marchlinski FE. Repetitive monomorphic tachycardia from the left ventricular outflow tract: electrocardiographic patterns consistent with a left ventricular site of origin. *J Am Coll Cardiol* 1997;29:1023-7.
379. Chinushi M, Aizawa Y, Takahashi K, Kitazawa H, Shibata A. Radiofrequency catheter ablation for idiopathic right ventricular tachycardia with special reference to morphological variation and long-term outcome. *Heart* 1997;78:255-61.
380. Haissaguerre M, Shoda M, Jais P, Nogami A, Shah DC, Kautzner J et al. Mapping and ablation of idiopathic ventricular fibrillation. *Circulation* 2002;106:962-7.
381. Joshi S, Wilber DJ. Ablation of idiopathic right ventricular outflow tract tachycardia: current perspectives. *J Cardiovasc Electrophysiol* 2005;16(Suppl. 1):S52-8.
382. Kaseno K, Tada H, Ito S, Tadokoro K, Hashimoto T, Miyaji K et al. Ablation of idiopathic ventricular tachycardia in two separate regions of the outflow tract: prevalence and electrocardiographic characteristics. *Pacing Clin Electrophysiol* 2007;30(Suppl. 1):S88-93.
383. Kottkamp H, Chen X, Hindricks G, Willems S, Haverkamp W, Wichter T et al. Idiopathic left ventricular tachycardia: new insights into electrophysiological characteristics and radiofrequency catheter ablation. *Pacing Clin Electrophysiol* 1995;18:1285-97.
384. Miles WM. Idiopathic ventricular outflow tract tachycardia: where does it originate? *J Cardiovasc Electrophysiol* 2001;12:536-7.
385. Miller JM, Pezeshkian NG, Yadav AV. Catheter mapping and ablation of right ventricular outflow tract ventricular tachycardia. *J Cardiovasc Electrophysiol* 2006;17:800-2.
386. Proclemer A, Ciani R, Feruglio GA. Right ventricular tachycardia with left bundle branch block and inferior axis morphology: clinical and arrhythmological characteristics in 15 patients. *Pacing Clin Electrophysiol* 1989;12:977-89.
387. Sanders P, Hsu LF, Hocini M, Jais P, Takahashi Y, Rotter M et al. Mapping and ablation of ventricular fibrillation. *Minerva Cardioangiol* 2004;52:171-81.
388. Sumitomo N, Harada K, Nagashima M, Yasuda T, Nakamura Y, Aragaki Y et al. Catecholaminergic polymorphic ventricular tachycardia: electrocardiographic characteristics and optimal therapeutic strategies to prevent sudden death. *Heart* 2003;89:66-70.
389. Movsowitz C, Schwartzman D, Callans DJ, Preminger M, Zado E, Gottlieb CD et al. Idiopathic right ventricular outflow tract tachycardia: narrowing the anatomic location for successful ablation. *Am Heart J* 1996;131:930-36.
390. Coggins DL, Lee RJ, Sweeney J, Chein WW, Van HG, Epstein L et al. Radiofrequency catheter ablation as a cure for idiopathic tachycardia of both left and right ventricular origin. *J Am Coll Cardiol* 1994;23:1333-41.
391. Hachiya H, Aonuma K, Yamauchi Y, Harada T, Igawa M, Nogami A et al. Electrocardiographic characteristics of left ventricular outflow tract tachycardia. *Pacing Clin Electrophysiol* 2000;23(Pt 2):1930-4.
392. Hirasawa Y, Miyauchi Y, Iwasaki YK, Kobayashi Y. Successful radiofrequency catheter ablation of epicardial left ventricular outflow tract tachycardia from the anterior interventricular coronary vein. *J Cardiovasc Electrophysiol* 2005;16:1378-80.
393. Ito S, Tada H, Naito S, Kurosaki K, Ueda M, Shinbo G et al. Simultaneous mapping in the left sinus of valsalva and coronary venous system predicts successful catheter ablation from the left sinus of valsalva. *Pacing Clin Electrophysiol* 2005;28(Suppl. 1):S150-4.
394. Kanagaratnam L, Tomassoni G, Schweikert R, Pavia S, Bash D, Beheiry S et al. Ventricular tachycardias arising from the aortic sinus of valsalva: an underrecognized variant of left outflow tract ventricular tachycardia. *J Am Coll Cardiol* 2001;37:1408-14.
395. Kumagai K, Yamauchi Y, Takahashi A, Yokoyama Y, Sekiguchi Y, Watanabe J et al. Idiopathic left ventricular tachycardia originating from the mitral annulus. *J Cardiovasc Electrophysiol* 2005;16:1029-36.
396. Sekiguchi Y, Aonuma K, Takahashi A, Yamauchi Y, Hachiya H, Yokoyama Y et al. Electrocardiographic and electrophysiologic characteristics of ventricular tachycardia originating within the pulmonary artery. *J Am Coll Cardiol* 2005;45:887-95.
397. Timmermans C, Rodriguez LM, Crijns HJ, Moorman AF, Wellens HJ. Idiopathic left bundle-branch block-shaped ventricular tachycardia may originate above the pulmonary valve. *Circulation* 2003;108:1960-7.
398. Yamauchi Y, Aonuma K, Takahashi A, Sekiguchi Y, Hachiya H, Yokoyama Y et al. Electrocardiographic characteristics of repetitive monomorphic right ventricular tachycardia originating near the His-bundle. *J Cardiovasc Electrophysiol* 2005;16:1041-8.
399. Yamauchi Y, Aonuma K, Sekiguchi Y, Obayashi T, Kumagai K, Isobe M. Successful radiofrequency ablation of ventricular premature contractions within the coronary sinus. *Pacing Clin Electrophysiol* 2005;28:1250-2.
400. Farzaneh-Far A, Lerman BB. Idiopathic ventricular outflow tract tachycardia. *Heart* 2005;91:136-8.
401. Tandri H, Bluemke DA, Ferrari VA, Bomma C, Nasir K, Rutberg J et al. Findings on magnetic resonance imaging of idiopathic right ventricular outflow tachycardia. *Am J Cardiol* 2004;94:1441-5.
402. Globits S, Kreiner G, Frank H, Heinz G, Klaar U, Frey B et al. Significance of morphological abnormalities detected by MRI in patients undergoing successful ablation of right ventricular outflow tract tachycardia. *Circulation* 1997;96:2633-40.
403. Krittayaphong R, Saiviroonporn P, Boonyasirinant T, Nakyen S, Thanapiboonpol P, Watanaprakarnchai W et al. Magnetic resonance imaging abnormalities in right ventricular outflow tract tachycardia and the prediction of radiofrequency ablation outcome. *Pacing Clin Electrophysiol* 2006;29:837-45.
404. Proclemer A, Basadonna PT, Slavich GA, Miani D, Fresco C, Fioretti PM. Cardiac magnetic resonance imaging findings in patients with right ventricular outflow tract premature contractions. *Eur Heart J* 1997;18:2002-10.
405. Sinha S, Calkins H. Idiopathic right ventricular outflow tract tachycardia: no longer idiopathic? *J Cardiovasc Electrophysiol* 2006;17:776.
406. Iwai S, Cantillon DJ, Kim RJ, Markowitz SM, Mittal S, Stein KM, Shah BK et al. Right and left ventricular outflow tract tachycardias: evidence for a common electrophysiologic mechanism. *J Cardiovasc Electrophysiol* 2006;17:1052-8.
407. Nakagawa M, Takahashi N, Nobe S, Ichinose M, Ooie T, Yufu F et al. Gender differences in various types of idiopathic ventricular tachycardia. *J Cardiovasc Electrophysiol* 2002;13:633-8.
408. Marchlinski FE, Deely MP, Zado ES. Sex-specific triggers for right ventricular outflow tract tachycardia. *Am Heart J* 2000;139:1009-13.
409. Wilber DJ, Baerman J, Olshansky B, Kall J, Kopp D. Adenosine-sensitive ventricular tachycardia. Clinical characteristics and response to catheter ablation. *Circulation* 1993;87:126-34.
410. Lerman BB, Stein KM, Markowitz SM, Mittal S, Iwai S. Ventricular tachycardia in patients with structurally normal hearts. In: Zipes DP ed. *Cardiac Electrophysiology: from Cell to Bedside*. Philadelphia: Saunders; 2004. p668-82.
411. Noda T, Shimizu W, Taguchi A, Aiba T, Satomi K, Suyama K et al. Malignant entity of idiopathic ventricular fibrillation and polymorphic ventricular tachycardia initiated by premature extrasystoles originating from the right ventricular outflow tract. *J Am Coll Cardiol* 2005;46:1288-94.
412. Viskin S, Rosso R, Rogowski O, Belhassen B. The "short-coupled" variant of right ventricular outflow ventricular tachycardia: a not-so-benign form of benign ventricular tachycardia? *J Cardiovasc Electrophysiol* 2005;16:912-6.
413. Viskin S, Antzelevitch C. The cardiologists' worst nightmare sudden death from "benign" ventricular arrhythmias. *J Am Coll Cardiol* 2005;46:1295-7.
414. Tada H, Hiratsugu T, Naito S, Kurosaki K, Ueda M, Ito S et al. Prevalence and characteristics of idiopathic outflow tract tachycardia with QRS alteration following catheter ablation requiring additional radiofrequency ablation at a different point in the outflow tract. *Pacing Clin Electrophysiol* 2004;27:1240-9.
415. Boulos M, Lashevsky I, Gepstein L. Usefulness of electroanatomical mapping to differentiate between right ventricular outflow tract tachycardia and arrhythmogenic right ventricular dysplasia. *Am J Cardiol* 2005;95:935-40.
416. Sticherling C, Zabel M. Arrhythmogenic right ventricular dysplasia presenting as right ventricular outflow tract tachycardia. *Europace* 2005;7:345-7.
417. Weerasooriya R, Hsu LF, Scavee C, Sanders P, Hocini M, Cabrera JA et al. Catheter ablation of ventricular fibrillation in structurally normal hearts targeting the RVOT and Purkinje ectopy. *Herz* 2003;28:598-606.
418. Nasir K, Bomma C, Tandri H, Roguin A, Dalal D, Prakasa K et al. Electrocardiographic features of arrhythmogenic right ventricular dysplasia/cardiomyopathy according to disease severity: a need to broaden diagnostic criteria. *Circulation* 2004;110:1527-34.
419. Arya A, Haghjoo M, Emkanjoo Z, Sadr-Ameli MA. Coronary sinus mapping to differentiate left versus right ventricular outflow tract tachycardias. *Europace* 2005;7:428-32.
420. Yamada T, McElderry HT, Doppalapudi H, Kay GN. Ventricular tachycardia with a myocardial fibre travelling from the origin in the right aortic sinus cusp to the epicardial breakout site of the right ventricular outflow tract. *Europace* 2008;10:469-70.
421. Hachiya H, Aonuma K, Yamauchi Y, Igawa M, Nogami A, Iesaka Y. How to diagnose, locate, and ablate coronary cusp ventricular tachycardia. *J Cardiovasc Electrophysiol* 2002;13:551-6.
422. Lin D, Ilkhanoff L, Gerstenfeld E, Dixit S, Beldner S, Bala R et al. Twelve-lead electrocardiographic characteristics of the aortic cusp region guided by intracardiac echocardiography and electroanatomic mapping. *Heart Rhythm* 2008;5:663-9.
423. Tada H, Nogami A, Naito S, Fukazawa H, Horie Y, Kubota S et al. Left ventricular epicardial outflow tract tachycardia: a new distinct subgroup of outflow tract tachycardia. *Jpn Circ J* 2001;65:723-30.
424. Yang Y, Saenz LC, Varosy PD, Badhwar N, Tan JH, Kilicaslan F et al. Using the initial vector from surface electrocardiogram to distinguish the site of outflow tract tachycardia. *Pacing Clin Electrophysiol* 2007;30:891-8.

425. Dixit S, Gerstenfeld EP, Callans DJ, Marchlinski FE. Electrocardiographic patterns of superior right ventricular outflow tract tachycardias: distinguishing septal and free-wall sites of origin. *J Cardiovasc Electrophysiol* 2003;14:1–7.
426. Bala R, Marchlinski FE. Electrocardiographic recognition and ablation of outflow tract ventricular tachycardia. *Heart Rhythm* 2007;4:366–70.
427. Chun KR, Satomi K, Kuck KH, Ouyang F, Antz M. Left ventricular outflow tract tachycardia including ventricular tachycardia from the aortic cusps and epicardial ventricular tachycardia. *Herz* 2007;32:226–32.
428. Aiba T, Shimizu W, Taguchi A, Suyama K, Kurita T, Aihara N et al. Clinical usefulness of a multielectrode basket catheter for idiopathic ventricular tachycardia originating from right ventricular outflow tract. *J Cardiovasc Electrophysiol* 2001; 12:511–7.
429. Greil GF, Gass M, Kuehlkamp V, Botnar RM, Wolf I, Miller S et al. Radiofrequency ablation of right ventricular outflow tract tachycardia using a magnetic resonance 3D model for interactive catheter guidance. *Clin Res Cardiol* 2006; 95:610–3.
430. Saleem MA, Burkett S, Passman R, Dibs S, Engelstein ED, Kadish AH et al. New simplified technique for 3D mapping and ablation of right ventricular outflow tract tachycardia. *Pacing Clin Electrophysiol* 2005;28:397–403.
431. Amerendral JPR. Radiofrequency Catheter Ablation of Idiopathic Right Ventricular Outflow Tract Tachycardia. Armonk, NY: Futura; 1998.
432. Rodriguez LM, Smeets JL, Timmermans C, Wellens HJ. Predictors for successful ablation of right- and left-sided idiopathic ventricular tachycardia. *Am J Cardiol* 1997;79:309–14.
433. Soejima Y, Aonuma K, Iesaka Y, Isobe M. Ventricular unipolar potential in radiofrequency catheter ablation of idiopathic non-reentrant ventricular outflow tachycardia. *Jpn Heart J* 2004;45:749–60.
434. Gerstenfeld EP, Dixit S, Callans DJ, Rajawat Y, Rho R, Marchlinski FE. Quantitative comparison of spontaneous and paced 12-lead electrocardiogram during right ventricular outflow tract ventricular tachycardia. *J Am Coll Cardiol* 2003; 41:2046–53.
435. Krittayaphong R, Sriratanasathavorn C, Dumavibhat C, Pumprueg S, Boonyapisit W, Pooranawattanukul S et al. Electrocardiographic predictors of long-term outcomes after radiofrequency ablation in patients with right-ventricular outflow tract tachycardia. *Europace* 2006;8:601–6.
436. Vestal M, Wen MS, Yeh SJ, Wang CC, Lin FC, Wu D. Electrocardiographic predictors of failure and recurrence in patients with idiopathic right ventricular outflow tract tachycardia and ectopy who underwent radiofrequency catheter ablation. *J Electrocardiol* 2003;36:327–32.
437. Frey B, Kreiner G, Fritsch S, Veit F, Gossinger HD. Successful treatment of idiopathic left ventricular outflow tract tachycardia by catheter ablation or minimally invasive surgical cryoablation. *Pacing Clin Electrophysiol* 2000;23: 870–6.
438. Krebs ME, Krause PC, Engelstein ED, Zipes DP, Miles WM. Ventricular tachycardias mimicking those arising from the right ventricular outflow tract. *J Cardiovasc Electrophysiol* 2000;11:45–51.
439. Kumagai K, Fukuda K, Wakayama Y, Sugai Y, Hirose M et al. Electrocardiographic characteristics of the variants of idiopathic left ventricular outflow tract ventricular tachyarrhythmias. *J Cardiovasc Electrophysiol* 2008;19:495–501.
440. Yamada T, Yoshida N, Murakami Y, Okada T, Muto M, Murohara T et al. Electrocardiographic characteristics of ventricular arrhythmias originating from the junction of the left and right coronary sinuses of valsalva in the aorta: the activation pattern as a rationale for the electrocardiographic characteristics. *Heart Rhythm* 2008;5:184–92.
441. Tada H, Naito S, Ito S, Kurosaki K, Ueda M, Shinbo G et al. Significance of two potentials for predicting successful catheter ablation from the left sinus of valsalva for left ventricular epicardial tachycardia. *Pacing Clin Electrophysiol* 2004; 27:1053–9.
442. Kaseno K, Tada H, Tanaka S, Goto K, Yokokawa M, Hiramatsu S et al. Successful catheter ablation of left ventricular epicardial tachycardia originating from the great cardiac vein: a case report and review of the literature. *Circ J* 2007;71:1983–8.
443. Lin D, Hsia HH, Gerstenfeld EP, Dixit S, Callans DJ, Nayak H et al. Idiopathic fascicular left ventricular tachycardia: linear ablation lesion strategy for noninducible or nonsustained tachycardia. *Heart Rhythm* 2005;2:934–9.
444. Tada H, Nogami A, Naito S, Tomita T, Oshima S, Taniguchi K et al. Retrograde Purkinje potential activation during sinus rhythm following catheter ablation of idiopathic left ventricular tachycardia. *J Cardiovasc Electrophysiol* 1998;9: 1218–24.
445. Tsuchiya T, Okumura K, Honda T, Honda T, Iwasa A, Yasue H et al. Significance of late diastolic potential preceding Purkinje potential in verapamil-sensitive idiopathic left ventricular tachycardia. *Circulation* 1999;99:2408–13.
446. Wen MS, Yeh SJ, Wang CC, Lin FC, Wu D. Successful radiofrequency ablation of idiopathic left ventricular tachycardia at a site away from the tachycardia exit. *J Am Coll Cardiol* 1997;30:1024–31.
447. Nogami A, Naito S, Tada H, Taniguchi K, Okamoto Y, Nishimura S et al. Demonstration of diastolic and presystolic Purkinje potentials as critical potentials in a macroreentry circuit of verapamil-sensitive idiopathic left ventricular tachycardia. *J Am Coll Cardiol* 2000;36:811–23.
448. Arya A, Haghjoo M, Emkanjoo Z, Fazelifar AF, Dehghani MR, Heydari A et al. Comparison of presystolic Purkinje and late diastolic potentials for selection of ablation site in idiopathic verapamil sensitive left ventricular tachycardia. *J Interv Card Electrophysiol* 2004;11:135–41.
449. Verma A, Kilicaslan F, Marrouche NF, Minor S, Khan M, Wazni O et al. Prevalence, predictors, and mortality significance of the causative arrhythmia in patients with electrical storm. *J Cardiovasc Electrophysiol* 2004;15: 1265–70.
450. Survivors of out-of-hospital cardiac arrest with apparently normal heart. Need for definition and standardized clinical evaluation. Consensus Statement of the Joint Steering Committees of the Unexplained Cardiac Arrest Registry of Europe and of the Idiopathic Ventricular Fibrillation Registry of the United States. *Circulation* 1997;95:265–72.
451. Belhassen B, Viskin S. Idiopathic ventricular tachycardia and fibrillation. *J Cardiovasc Electrophysiol* 1993;4:356–68.
452. Meissner MD, Lehmann MH, Steinman RT, Mosteller RD, Akhtar M, Calkins H et al. Ventricular fibrillation in patients without significant structural heart disease: a multicenter experience with implantable cardioverter-defibrillator therapy. *J Am Coll Cardiol* 1993;21:1406–12.
453. Nademanee K, Taylor R, Bailey WE, Rieders DE, Kosar EM. Treating electrical storm: sympathetic blockade versus advanced cardiac life support-guided therapy. *Circulation* 2000;102:742–7.
454. Zipes DP, Camm AJ, Borggrefe M, Buxton AE, Chaitman B, Fromer M et al. ACC/AHA/ESC 2006 guidelines for management of patients with ventricular arrhythmias and the prevention of sudden cardiac death: a report of the American College of Cardiology/American Heart Association Task Force and the European Society of Cardiology Committee for Practice Guidelines (Writing Committee to Develop Guidelines for Management of Patients With Ventricular Arrhythmias and the Prevention of Sudden Cardiac Death). *J Am Coll Cardiol* 2006;48:e247–346.
455. Haissaguerre M, Shah DC, Jais P, Shoda M, Kautzner J, Arentz T et al. Role of Purkinje conducting system in triggering of idiopathic ventricular fibrillation. *Lancet* 2002;359:677–8.
456. Tracy CM, Akhtar M, DiMarco JP, Packer DL, Weitz HH, Creager MA et al. American College of Cardiology/American Heart Association 2006 update of the clinical competence statement on invasive electrophysiology studies, catheter ablation, and cardioversion: a report of the American College of Cardiology/American Heart Association/American College of Physicians Task Force on Clinical Competence and Training developed in collaboration with the Heart Rhythm Society. *J Am Coll Cardiol* 2006;48:1503–17.
457. Wittkamp FH, Wever EF, Vos K, Geleijns J, Schalijs MJ, van der Tol J et al. Reduction of radiation exposure in the cardiac electrophysiology laboratory. *Pacing Clin Electrophysiol* 2000;23(Pt 1):1638–44.
458. Lickfett L, Mahesh M, Vasamreddy C, Bradley D, Jayam V, Eldadah Z et al. Radiation exposure during catheter ablation of atrial fibrillation. *Circulation* 2004;110:3003–10.
459. Nickoloff EL, Lu ZF, Dutta A, So J, Balter S, Moses J. Influence of flat-panel fluoroscopic equipment variables on cardiac radiation doses. *Cardiovasc Intervent Radiol* 2007;30:169–76.
460. Dragusin O, Weerasooriya R, Jais P, Hocini M, Ector J, Takahashi Y et al. Evaluation of a radiation protection cabin for invasive electrophysiological procedures. *Eur Heart J* 2007;28:183–9.
461. Fisher JD, Cain ME, Ferinand KC, Fisch C, Kennedy JW, Kutalek ST et al. Catheter ablation for cardiac arrhythmias: clinical applications, personnel and facilities. *J Am Coll Cardiol* 1994;24:828–33.
462. Buxton AE, Marchlinski FE, Doherty JU, Cassidy DM, Vassallo JA, Flores BT et al. Repetitive, monomorphic ventricular tachycardia: clinical and electrophysiologic characteristics in patients with and patients without organic heart disease. *Am J Cardiol* 1984;54:997–1002.
463. Exner DV, Pinski SL, Wyse DG, Renfroe EG, Follmann D, Gold M et al. Electrical storm presages nonsudden death: the antiarrhythmics versus implantable defibrillators (AVID) trial. *Circulation* 2001;103:2066–71.